

**NHS Greater Glasgow & Clyde**

# **CONGENITAL ANOMALIES SURVEILLANCE**

## **2012-2013**

---

**REVIEW OF DATA RELATING TO CONGENITAL  
ANOMALIES DETECTED IN NHS GG&C  
BETWEEN  
1<sup>ST</sup> APRIL 2012 AND 31<sup>ST</sup> MARCH 2013**

**Dr. James Robins**

Source data provided by Hilary Jordan of Information Services

**Final**

23<sup>rd</sup> February 2014

## Table of Contents

Table of Contents.....	2
Definitions.....	5
1. Core Data .....	7
1.1. Case based review.....	7
1.2. Abnormality based review .....	10
1.3. Maternal Age .....	11
1.4. Gender .....	12
1.5. Multiple Pregnancy .....	12
2. Point of Diagnosis.....	14
2.1. At Birth .....	15
2.2. Within 1 <sup>st</sup> week .....	17
2.3. Between 1-4 weeks.....	17
2.4. Diagnosed after 1 month but within 1 year.....	17
2.5. Diagnosis after 12 months .....	18
2.6. Prenatal Diagnosis.....	18
2.7. Unknown.....	20
2.8. Post-mortem .....	20
3. Pregnancy Outcome.....	21
3.1. Live-birth .....	22
3.2. Stillbirth.....	23
3.3. Spontaneous Fetal Loss.....	23
3.4. Termination of Pregnancy.....	23
4. Review by Defined Abnormality .....	25
4.1. Endocrine & Metabolic Disorders .....	25
4.1.1. In-born Errors of Metabolism .....	25
4.1.2. Congenital Hypothyroidism, (E0310; E0312; E039) .....	25
4.1.3. Cystic Fibrosis, (E840; E841; E849) .....	26
4.1.4. Other Metabolic.....	26
4.2. Cranial & Spinal Abnormalities .....	27
4.2.1. Neural Tube Defect, (NTD).....	27
4.2.2. Holoprosencephaly, (Q042) .....	28
4.2.3. Microcephaly, (Q02X) .....	28
4.2.4. Hydrocephalus, (Q030, Q039).....	29
4.2.5. Other Cranial & Spinal Abnormalities .....	29
4.3. Cardiac & Circulatory .....	30
4.3.1. Hypoplastic Left Heart Syndrome, (Q234, Q248) .....	32

## Congenital Anomalies Report 2012-2013

4.3.2. Transposition of the Great Vessels, (Q203) .....	32
4.3.3. Fallot's Tetralogy, (Q213).....	33
4.3.4. Coarctation of the Aorta, (Q251) .....	33
4.3.5. Total Anomalous Pulmonary Venous Drainage, (TAPVD), (Q262).....	34
4.3.6. Ebstein's Anomaly, (Q225).....	34
4.4. Congenital Malformations of the Respiratory System.....	35
4.4.1. Sequestrations, Congenital Cystic Adenomatoid Malformation and Congenital Lobar Emphysema, (Q338, Q3380, P2500).....	35
4.5. Face & Neck .....	36
4.5.1. Cleft Lip & Palate, (Q 352, Q3539, Q3599, Q3690, Q3699, Q378, Q3799).....	36
4.5.2. Congenital Cavernous Lymphangioma, 'Cystic Hygroma', (D181, D1810).....	36
4.5.3. Pierre-Robin Sequence, (Q870) .....	37
4.5.4. Congenital Cataracts, (Q120) .....	37
4.5.5. Other Face & Neck .....	37
4.6. Gastrointestinal Abnormalities .....	38
4.6.1. Oesophageal Atresia, (Q391) .....	38
4.6.2. Imperforate Anus, Anal Stenosis & Anorectal Atresia, (Q4228, Q423) .....	38
4.6.3. Malrotation of Bowel, (Q433).....	38
4.6.4. Other Gastrointestinal Abnormalities.....	39
4.7. Renal & Urinary System .....	40
4.7.1. Renal Agenesis and Other Reduction Defects, (Q600, Q601, Q602) .....	40
4.7.2. Cystic Kidney Disease (Q611, Q614, Q6141).....	40
4.7.3. Congenital Obstructive Defects of Renal Pelvis & Malformation of Ureter, (Q62) .....	41
4.7.4. Other Congenital Malformations of the Kidney, (Q63) .....	41
4.7.5. Other Congenital Anormalities, (Q64) .....	42
4.7.6. Hypospadias, (Q540, Q541, Q542, Q549).....	42
4.8. Musculo-Skeletal Abnormalities .....	43
4.8.1. Congenital deformity of the hip, (Q651, Q6580, Q6581) .....	43
4.8.2. Achondroplasia, (Q774) .....	43
4.8.3. Talipes Equino Varus, (Q660).....	43
4.8.4. Limb Reduction Defects, (Q71, Q72). .....	44
4.8.5. Craniosynostosis (Q750) .....	44
4.8.6. Other Musculo-Skeletal Abnormalities.....	45
4.9. Abdominal Wall Defect .....	46
4.9.1. Congenital Diaphragmatic Hernia, (Q790).....	46
4.9.2. Gastroschisis, (Q793) .....	46
4.9.3. Exomphalos, (Q792).....	46
4.9.4. Other Abdominal Wall Defect, (Q795).....	46
4.9.5. Amniotic Band Sequence, (Q7980) .....	47

Congenital Anomalies Report 2012-2013

4.10. Chromosomal Abnormality.....	48
4.10.1. Trisomy 21 (Down Syndrome), (Q900, Q909).....	49
4.10.2. Trisomy 18, (Q910, Q913).....	50
4.10.3. Trisomy 13, (Q914, Q917).....	50
4.10.4. Turner Syndrome, (Q960, Q963, Q967).....	50
4.10.5. Triploidy, (Q927).....	50
4.10.6. Klinefelter Syndrome, (Q980).....	51
4.10.7. Other Genetic.....	51
Appendix 1.....	52
NHS Greater Glasgow & Clyde Maternities 1 <sup>st</sup> April 2012 – 31 <sup>st</sup> March 2013.....	52
Appendix 2.....	53
Case Prevalence Comparison, (per 10,000 births).....	53
Appendix 3.....	54
Prenatal Detection Rates: Comparison with ‘established’ data.....	54

## Definitions

A **congenital disorder**, or congenital disease, is a condition existing at birth. The disorder may be the result of genetic abnormality, errors of morphogenesis, the intrauterine environment, infection or chromosomal abnormality.

**Birth defect** is a widely used term for congenital malformation which is recognizable at birth. Congenital anomalies are of four clinically significant types.

- Malformations
- Deformations
- Disruptions
- Dysplasias

**Malformation:** In a malformation the development of a structure is arrested delayed or misdirected early in embryonic life and the effect is permanent.

**Deformations:** Are distinct from malformations in both timing and impact. They are conditions that arise from the application of mechanical stress to normally formed tissues. They may occur later in pregnancy and can be temporary.

**Disruptions:** Describes a complete breakdown of normal tissues

**Dysplasias:** Cellular abnormality of the originating tissue e.g. expansion of immature cells with a corresponding decrease in the number and location of mature cells.

Congenital disorders may consist of more than one abnormality. When multiple effects occur in a specified order the disorder is known as a **sequence**. When the order is not known it is called a **syndrome**.

**BINOCAR:** The British Isles Network of Congenital Anomaly Registers. A group of regional disease specific registers collecting information about congenital abnormalities occurring in England, Ireland, Scotland & Wales.

**EUROCAT:** European Surveillance of Congenital Anomalies. A study based on a network of population based registries for the epidemiological surveillance of congenital anomalies. It was started in 1979 and surveys more than 1.7M births per year in Europe.

**Incidence or Birth Prevalence?** The incidence is the rate of occurrence of new cases of a disease or condition over a specified period of time expressed as a ratio or percentage.

$$\text{Incidence} = \frac{\text{number of new cases over specified period of time}}{\text{size of population under consideration}}$$

In previous reports **incidence** has been used in preference to **prevalence**, which describes how frequently a disease or condition occurs in a specified population at a particular point in time.

The appropriate denominator for calculation of the incidence, (the size of the population under consideration who are initially disease free), is debatable. In the circumstances of this study it should be the number of maternities booked through antenatal services over the year 1<sup>st</sup> April 2012 and 31<sup>st</sup> March 2013, (n=15,857).

All congenital anomaly registers report the number of babies with anomalies born during a calendar year. Perhaps this should mean that they would all report incidence rates. However in practice the majority of congenital anomaly registers actually report prevalence estimates.

The reason given is that it is not possible to ascertain all 'new' cases of any particular anomaly as a proportion of pregnancies affected with an anomaly will miscarry spontaneously before being diagnosed. For example, although 15,857 women booked with NHS GG&C between 1<sup>st</sup> April 2012 and 31<sup>st</sup> March 2013, a total of 17,729 appointed referrals were made during the same time period. This means that at least 1872 pregnancies were 'lost' from time of referral to booking, (Appendix 1).

As a consequence other congenital anomaly registers will report prevalence estimates per 1,000 or 10,000 total births (live and stillbirths). These are referred to as birth prevalence estimates even though the pregnancy may not result in a 'birth' because of late miscarriage or termination of pregnancy for fetal anomaly.

**Prenatal Diagnosis:** A diagnosis of abnormality made in a live fetus at any gestation.

**Prenatal Screening:** Test for identifying a fetus that may be at a high risk for a defined congenital abnormality such as Down syndrome.

**Stillbirth:** Late fetal deaths from 24 completed week's gestation.

**Termination for fetal anomaly:** Deliberate ending of pregnancy, with intention that the fetus will not survive, following the prenatal diagnosis of major congenital anomaly

## 1. Core Data

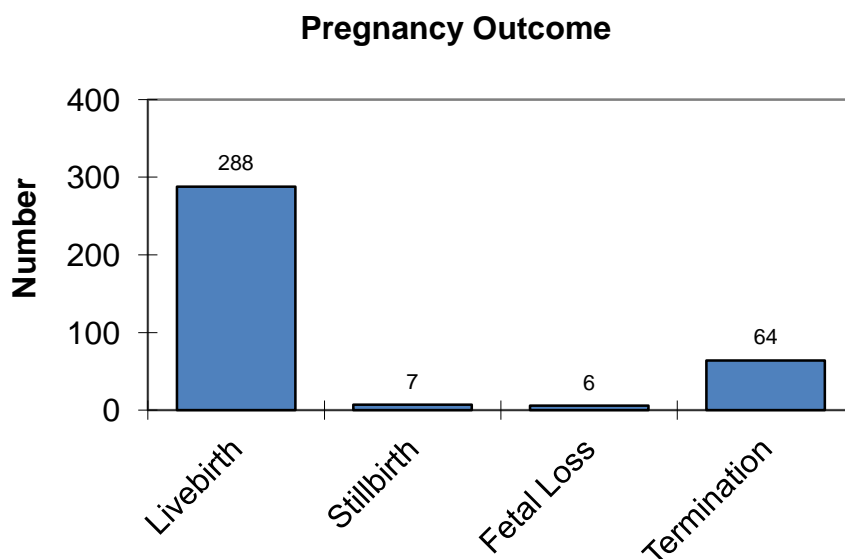
This report considers all live-births, stillbirths, fetal losses and terminations of pregnancy between 1<sup>st</sup> April 2012 and 31<sup>st</sup> March 2013 that were associated with one or more congenital abnormalities. Congenital anomaly data are collected from a number of different sources. The contents of the report are merely a 'snapshot'. The data set is constantly updated as further congenital abnormalities are recognized within the cohort. For example, since this report was initiated further data has been received from Medical Genetics increasing the number of primary chromosomal diagnoses.

### 1.1. Case based review

A total of 365 cases were identified from 363 pregnancies,<sup>1</sup> this is a 15.5% increase over the 316 cases described in the 2011-2012 review. Once again case ascertainment, (the proportion of notifications of congenital anomalies reported out of all cases of congenital abnormality in the population), would appear to have improved rather than any real increase in congenital anomaly.

The majority of cases were live-births, (288; 78.9%). There were 7 stillbirths (2%) and 6 fetal losses (1.6%). Termination of pregnancy following pre-natal diagnosis of abnormality accounted for 64 cases, (17.5%), (Figure 1.1).

Figure 1.1: Pregnancy Outcome, (n=365).



Overall a total of 579 abnormalities were classified in these 365 cases using the ICD10 system, the primary abnormality and a variable number of associated abnormalities. In 247 cases only the primary abnormality is listed. However in 118 cases, (32.3%), two or more abnormalities have been classified, (Figure 1.2). In one case a total of 7 abnormalities were defined.

The data on the 365 cases, including associated abnormalities, has been provided as a list which has been ordered on the basis of the primary abnormality as defined under ICD10, (Figure 1.3). This year additional information has been collected on gestational age at time of birth or termination, maternal age, birth order for multiple pregnancy and gender.

<sup>1</sup> Two sets of twins with each co-twin exhibiting an abnormality.

Figure 1.2: Abnormalities per case, (n=365).

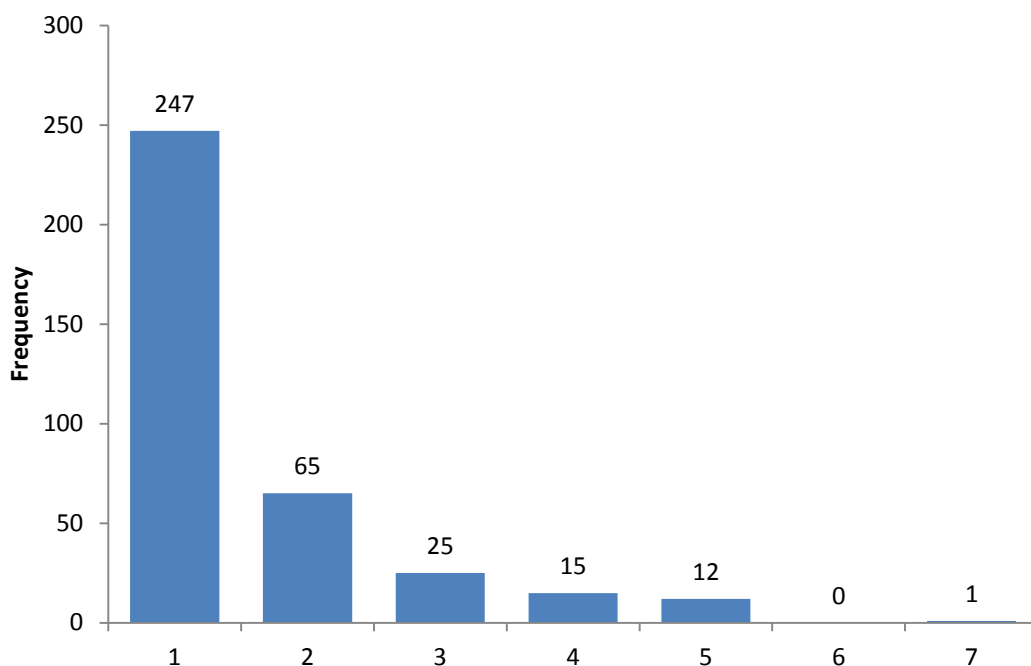
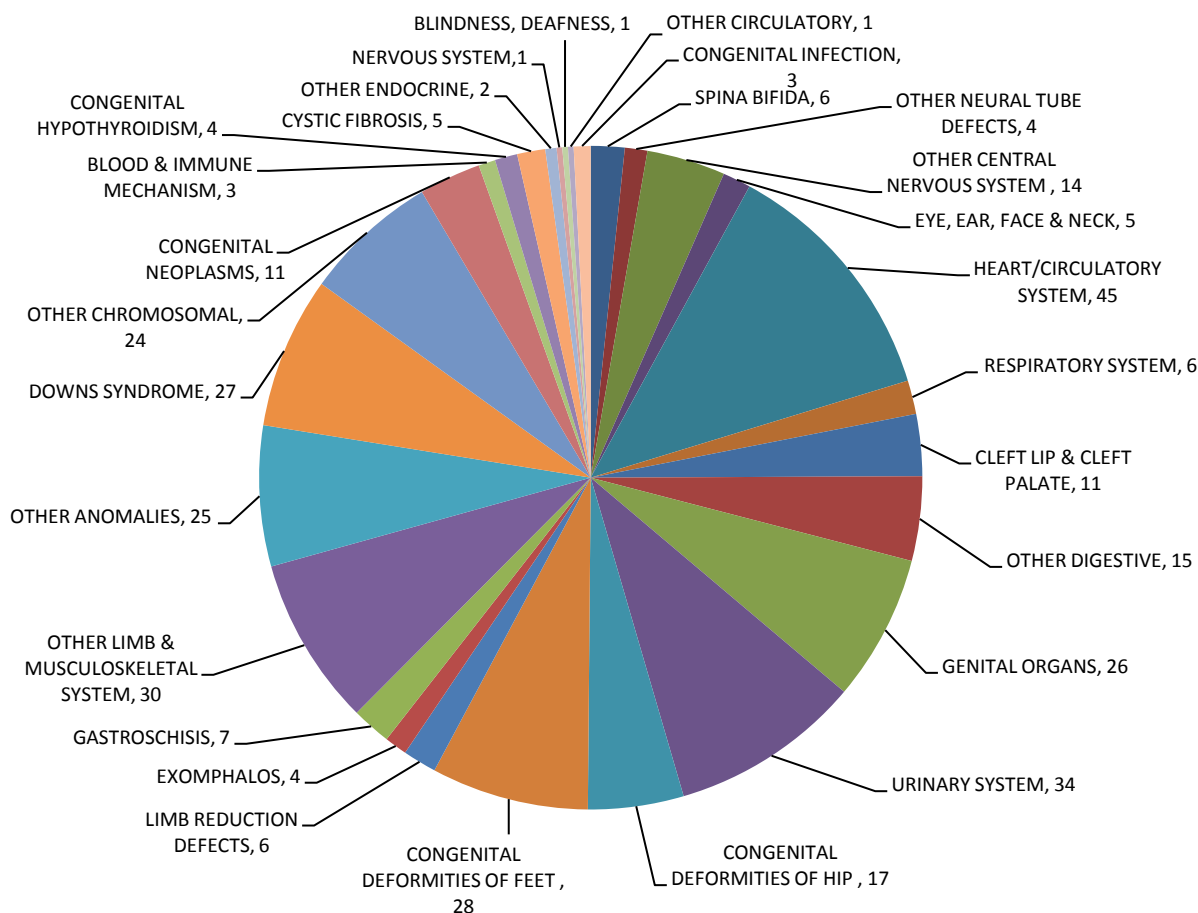


Figure 1.3: Classification according to Primary Abnormality (ICD10), (n=365).



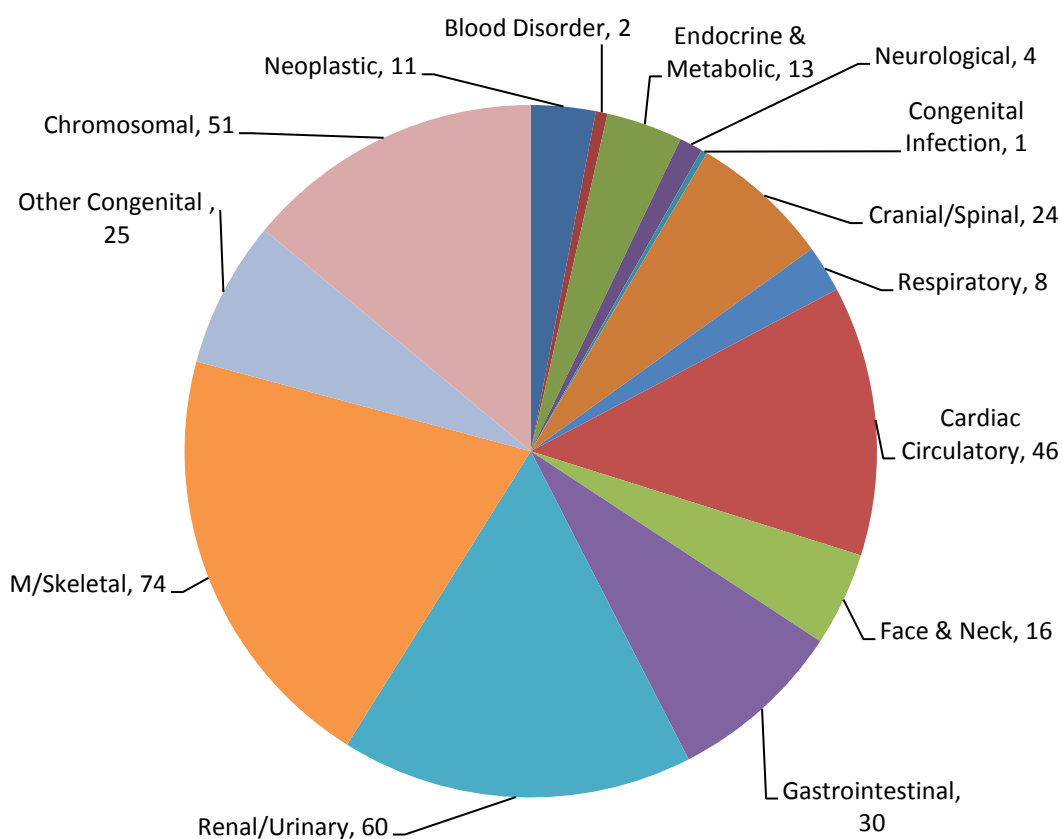


Abnormalities of the musculoskeletal system, ('Congenital Deformities of Hip', 'Congenital Deformities of Feet', 'Limb Reduction Defects' and 'Other Limb & Musculoskeletal System') are the commonest primary classification. A total of 81 cases, (22.2%) are classified as disorders of the musculoskeletal system under ICD10. This includes some cases of abdominal wall disruption not considered gastroschisis or exomphalos and all cases of amniotic band sequence. Congenital anomalies of the Genitourinary system, ('Genital Organs' and 'Urinary System'), are the next most common primary abnormality, (n=60; 16.4%).

In previous years Chromosomal abnormality, ('Down Syndrome' and 'Other Chromosomal Disorders'), has been the most common primary classification accounting for up to 23% of cases. Yet on this review a primary classification of Chromosomal abnormality is recorded in 51 cases, (13.9%).<sup>2</sup> Disorders of the Heart and Circulatory System, ('Circulatory System' and 'Other Circulatory'), are classified as the primary abnormality in a total of 46 cases, (12.6%). Cranial and spinal abnormality, ('Spina Bifida', 'Other Neural Tube Defects' and 'Other Central Nervous System'), is the preferred primary classification in 24 cases, (6.6%).

However some disorders, as classified and ordered under ICD10, are typically reviewed under other 'systems' and hence an aggregated and simplified chart based on primary abnormality is presented in Figure 1.4. This simplification also attempts to correct some of the errors inherent in ICD10. For example, 'Congenital Lobar Emphysema', (P2500), is listed as a 'Congenital Infection' under ICD10 rather than a primary disruption of broncho-pulmonary development.

**Figure 1.4: Simplified Classification by Primary Abnormality, (n=365).**



<sup>2</sup> Recent data received from Medical Genetics for the 2012-2013 cohort now classifies sixty-nine primary 'chromosomal' diagnoses, (18.9%).

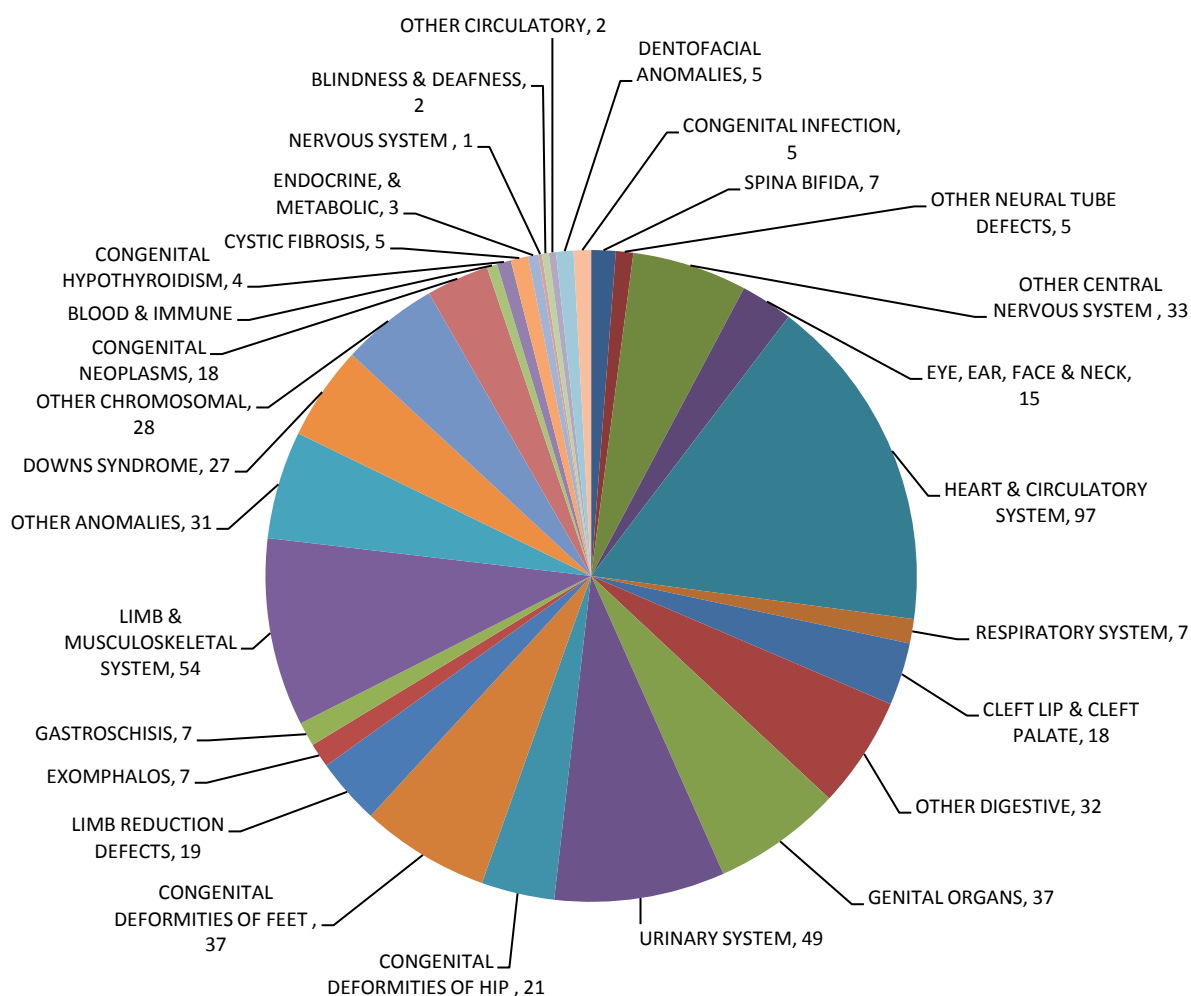
## 1.2. Abnormality based review

The situation becomes a little more complex when all of the 579 abnormalities, as defined under the ICD10 classification, are considered, (Figure 1.5). Disorders of the Musculoskeletal System still account for the majority of defined abnormalities, (n=131, 22.6%). Thereafter Cardiac & Circulatory abnormalities form the second most common grouping, (n=99, 17.1%). Genitourinary abnormalities remain prevalent accounting for 14.9% of all recorded congenital anomalies, (n=86).

The single most common abnormality was Talipes Equino Varus which was listed on thirty-five occasions, the majority, (n=27), as a primary diagnosis.

The birth prevalence for all abnormalities is 365 per 10,000 maternities. This is much higher than comparable data from both BINOCAR and EUROCAT.

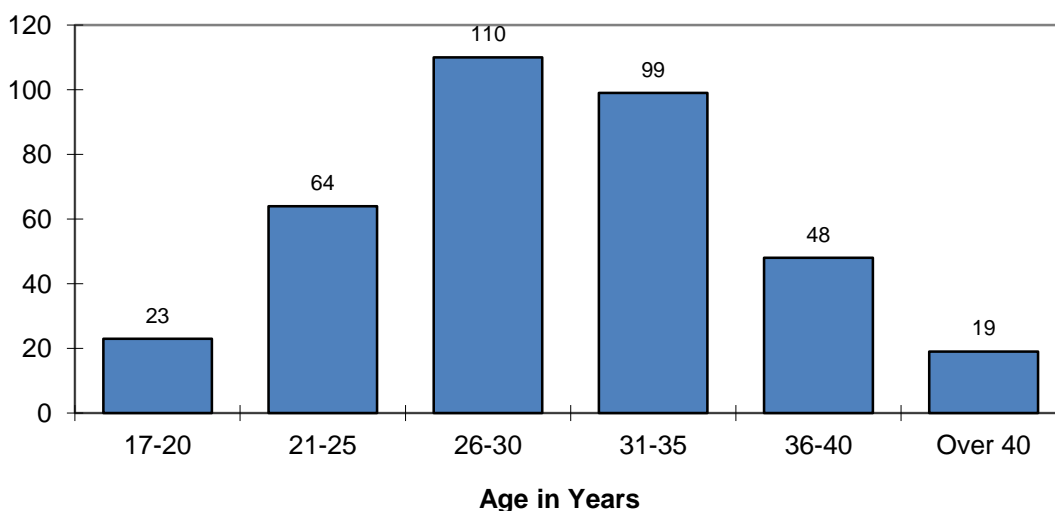
**Figure 1.5: Anomalies in any diagnostic position, (ICD10 & not mutually exclusive), (n=579)**



### 1.3. Maternal Age

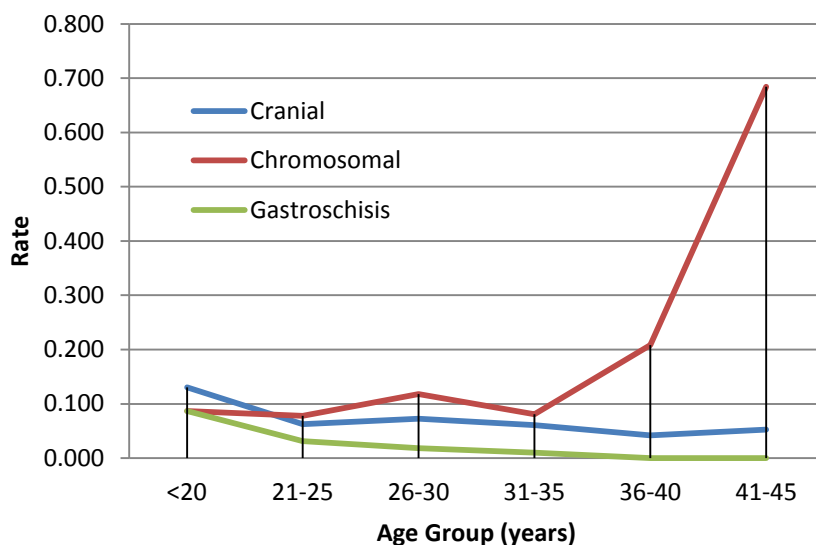
Older women who do become pregnant are more likely to have a baby affected by birth defects or genetic and chromosomal abnormality. Overall 363 pregnancies accounted for the 365 classified cases of abnormality. Maternal age at time of delivery, miscarriage or termination ranged from 17 to 44 years, (Figure 1.6). The mean age was 29.95 years. Although maternal age is recorded in the register no information is held on paternal age.

**Figure 1.6: Maternal age at delivery or loss, (n=363)**



Data from BINOCAR would suggest that mothers under the age of 20 years have the highest prevalence of non-chromosomal anomalies when compared with older mothers. In particular after excluding chromosomal anomalies the birth prevalence of nervous system anomalies and abdominal wall defects are higher in younger mothers when compared with older mothers. The birth prevalence of chromosomal anomalies increases with age. Similar trends can be seen within this data set although this analysis is, (at best), rudimentary, (Figure 1.7).

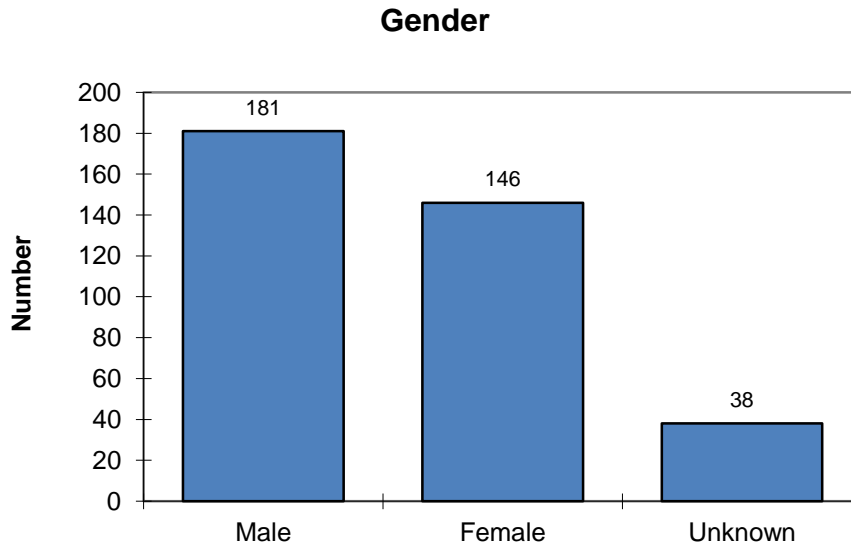
**Figure 1.7: Rate of index anomaly as proportion of all primary anomalies within each given age group.**



### 1.4. Gender

Gender is given for 327 cases. Congenital abnormality was more prevalent in males than females. In the remaining 38 it is recorded as unknown, (Figure 1.8).

**Figure 1.8: Fetal & Infant Gender, (n=365)**



The mean gestation at delivery for cases of 'unknown' gender is 15.8 weeks. They were either terminations, (n=35), or early spontaneous fetal losses, (n=3). In all but one case a prenatal diagnosis of abnormality was made. Indeed twenty cases were terminated following the prenatal diagnosis of chromosomal abnormality so it is likely that the genetic sex will be known.

### 1.5. Multiple Pregnancy

Eleven cases are recorded from twin pregnancies. There were two pregnancies where an abnormality was shared by both co-twins. Prenatal diagnosis of abnormality was achieved in both pregnancies.

Q660	CTEV-BILAT	Twin 1	Live-births; Delivered at 36 weeks gestation; Both male gender
Q660	CTEV-BILAT	Twin 2	
Q7800	OSTEOGENESIS IMPERFECTA	Twin 1	Live-births; Delivered at 35 weeks gestation; Both female gender
Q7800	OSTEOGENESIS IMPERFECTA	Twin 2	

There were seven other cases where only one twin had an abnormality. All were live-births.

E2500	21 HYDROXYLASE DEFICIENCY	Diagnosed in 1 <sup>st</sup> week of life
Q630	DUPLEX KIDNEY (L)	Late diagnosis
Q825	HAEMANGIOMA (L) TEMPLE	Diagnosed at birth
D1800	CAPILLARY HAEMANGIOMA	Diagnosed at birth
Q221	PULMONARY VALVE STENOSIS	Diagnosed in 1 <sup>st</sup> month of life
Q234	HYPOPLASTIC LEFT HEART	Prenatal diagnosis
Q542	HYPOSPADIAS-PENOSCROTAL	Prenatal diagnosis; Retractable testis

A total of 206 twin pregnancies were delivered to NHS GG&C residents during 2012-2013.

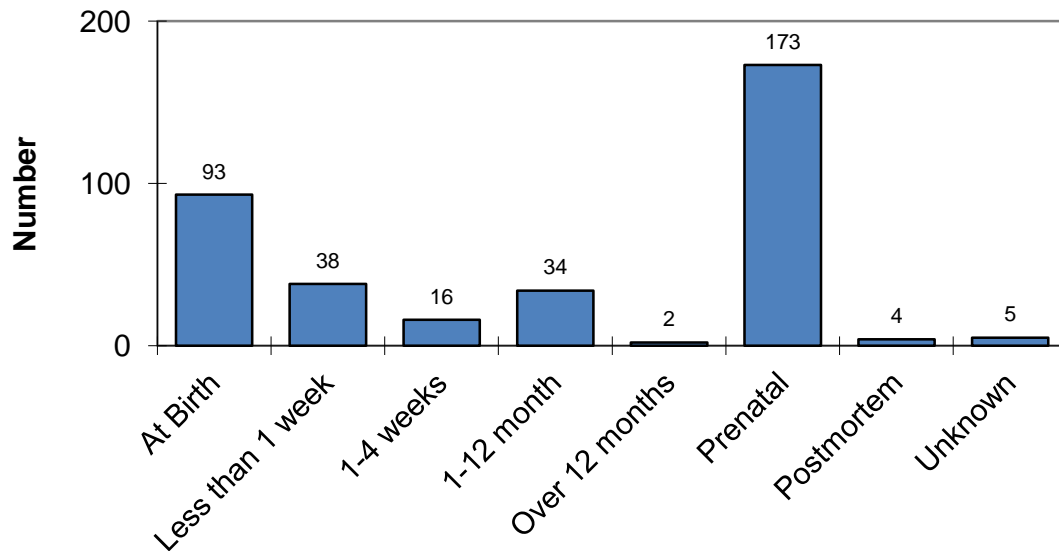
NOTE:-

The accurate prenatal diagnosis of hypospadias associated with retractile testis in a male second twin was a seemingly unlikely achievement. The explanation is relatively straightforward. The hypospadias was NOT detected on prenatal scan. Under EUROCAT definitions the 'point of diagnosis' or 'date of discovery' is the date on which the fetus or infant is first suspected or recognized as being malformed, even if the detailed diagnosis is not available. In this case the fetus was found to be severely growth retarded on prenatal scan and abnormality was suspected. The actual diagnosis of this primary congenital abnormality was made at birth.

## 2. Point of Diagnosis

Data are available for the 'point of diagnosis', or 'date of discovery' if it is preferred, (Figure 2.1). It should however be clear, given the case described in the last section, that this does not necessarily imply the point at which the primary abnormality was first recognized and some care must be exercised in interpreting the data.

**Figure 2.1: Point of Diagnosis, (n=365)**



Over 47.4%, (n=173), of primary abnormalities were diagnosed prenatally. In 93 cases, (25.5%), the diagnosis was made at birth or within the first week of life. Thirty-four cases, (9.3%), were diagnosed after the first month but within 1 year. Four cases, (1%), were diagnosed at post-mortem. In a further 5 cases the point of diagnosis is recorded as 'unknown'.

A chart demonstrating Point of Diagnosis for primary abnormality, as defined by the simplified classification described above, is produced, (Figure 2.2).

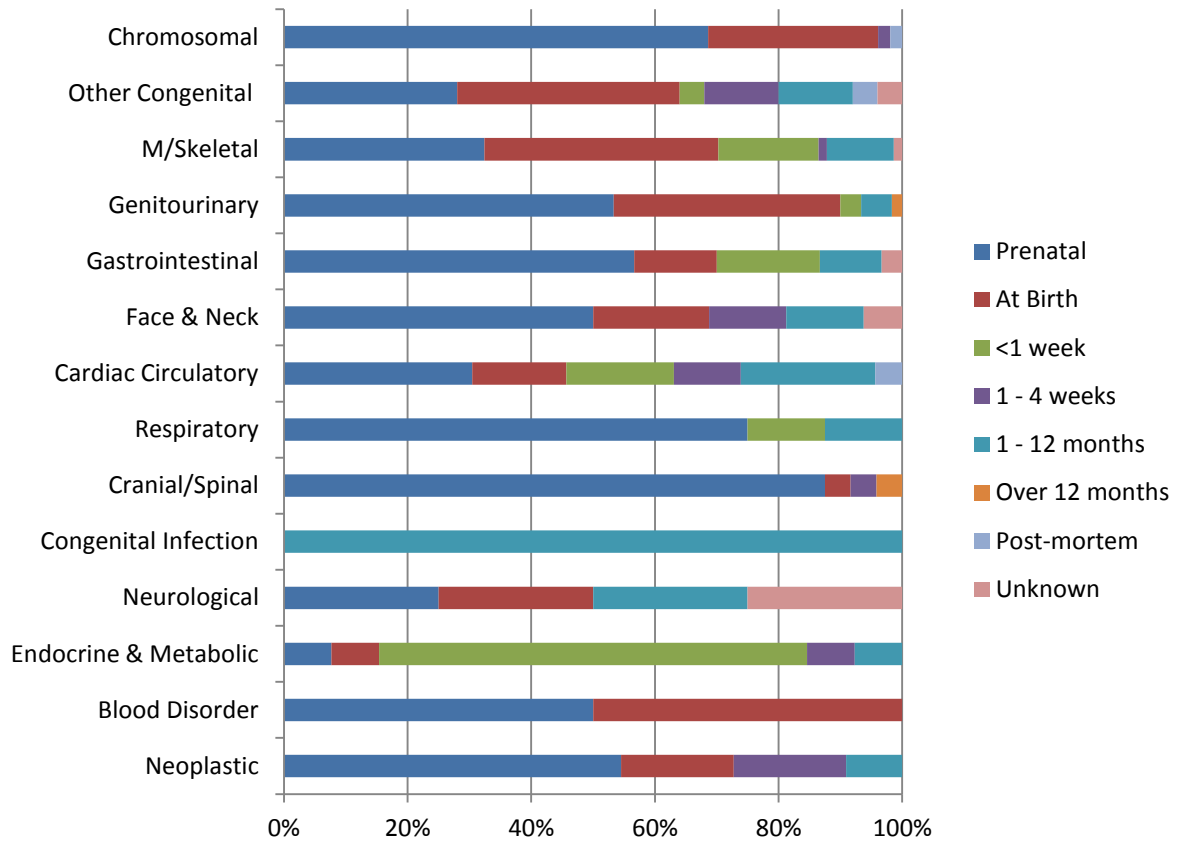
Typically most diagnoses of primary abnormality are made either antenatally or within the first week of life. Eighty-eight percent of all 'Cranial & Spinal' abnormalities and sixty-nine percent of 'Chromosomal' abnormalities are diagnosed prenatally. Furthermore, 75%, (n=6), of abnormalities of the respiratory system were diagnosed on antenatal scan.

The results of routine blood spot analysis dictate that 'Endocrine & Metabolic' disorders will usually be diagnosed around 1- 4 weeks.

Although the majority of primary 'Cardiac & Circulatory' disorders are picked up either on antenatal scan or during the first week of life, a good proportion, (22%), are not diagnosed until 1 – 12 months of life.

The two cases of 'Blood Disorder' were both Di George Syndrome (22q11.2 deletion). One was diagnosed at birth the other was a prenatal diagnosis. Clearly these cases could easily have been classified in a number of the ICD10 categories.

**Figure 2.2: Point of Diagnosis for Main ICD10 Category, (Simplified), (n=365)**



### 2.1. At Birth

Ninety-three primary abnormalities are coded as being diagnosed at birth, (Figure 2.3).

Once again disorders of the musculoskeletal system comprise the largest group, (n=28, 30%). The abnormalities seen included talipes equino varus, (n=12), arthrogryposis, (n=2), accessory digits, (n=3) and achondroplasia, (n=1).

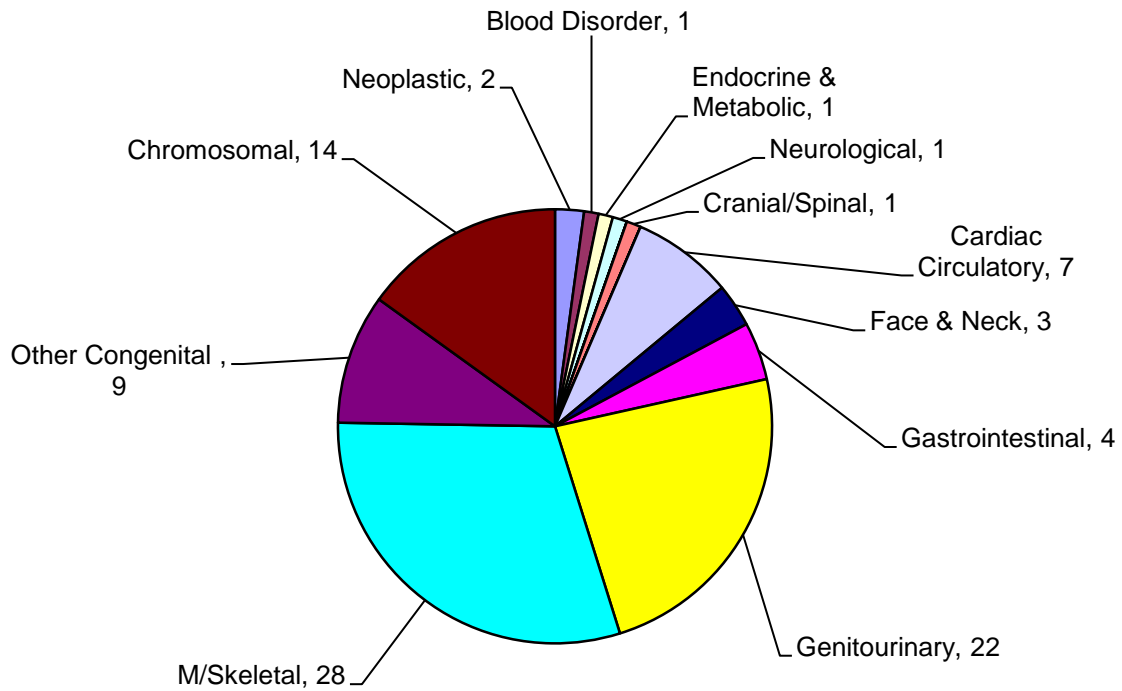
Disorders of the urogenital system are commonly diagnosed at birth. Hypospadias is the diagnosis in 18 of these cases. The two cases of ambiguous genitalia recorded as being diagnosed at birth were also associated with hypospadias.

Fourteen cases of Trisomy 21 were diagnosed at birth. Unfortunately there is no record of whether or not the mother’s had elected for prenatal screening in this data but this could be determined through linkage to the Pregnancy & Newborn Screening Programme, (PNBS). A linkage exercise has been performed on data from 2011-2012.<sup>3</sup>

Cardiac anomalies diagnosed at birth included single cases of transposition of the great arteries, Tetralogy of Fallot, Coarctation of the aorta, tricuspid atresia and total anomalous pulmonary venous drainage. Two cases of Ebstein’s anomaly, one described as severe, were also diagnosed at birth.

<sup>3</sup> Simpson L. & Robins J. (2013). In 2011-2012 fifty percent of women with an identified Down syndrome affected pregnancy either declined initial screening or declined a diagnostic test following a high risk assessment. All consented to a fetal anomaly scan. The most common outcome following prenatal diagnosis of Down syndrome was termination of pregnancy.

**Figure 2.3: Diagnosis made at Birth by Primary Abnormality (ICD10), (n=93)**



Cleft palate was diagnosed at birth in 3 cases.

Other abnormalities diagnosed at birth included cases of Sturge-Weber syndrome, Goldenhar syndrome, Stickler syndrome and Metopic Synostosis. The latter is an uncommon form, (4-10%), of craniosynostosis where the affected individual develops a pointed, 'triangular' scalp.

Sturge-Weber syndrome is a sporadic disorder associated with a facial haemangioma, venous angioma of the leptomeninges and choroidal angioma. Clinical features include epilepsy, (75-90%), learning disability, hemiparesis and glaucoma.

Stickler Syndrome is in fact a group of hereditary conditions. The majority are associated with a distinctive facial appearance, eye abnormalities, hearing loss, joint problems and micrognathia. The condition(s) is also known as hereditary progressive arthro-ophthalmopathy. Types I, II and III show an autosomal dominant pattern of inheritance whereas Types IV and V are autosomal recessive.

Gastrointestinal disorders included 3 cases of imperforate anus and 1 case of Hirschsprung's Disease.

There were two cases where Congenital Lamellar Ichthyosis was diagnosed at birth. Ichthyosis is a mixed group of conditions where persistent scaling of the skin is the predominant feature. It may be the consequence of a number of genetic disorders.

The two cases of congenital neoplastic disease were both capillary haemangiomas.



## 2.2. Within 1<sup>st</sup> week

Congenital abnormality was diagnosed in 38 cases during the first week of life. The majority were congenital abnormalities of the musculoskeletal system (n=12; 31.6%). Ten of these cases, (all female), related to the diagnosis of congenital dysplasia of the hip, (CDH).

As might be expected endocrine and metabolic abnormalities feature and account for 23.7% of all diagnoses made in the first week of life, (n=9). There were three cases of congenital hypothyroidism and four cases of cystic fibrosis. Other diagnoses within this category included a case of 21-hydroxylase deficiency and a case of Pendred Syndrome, (see later).

Three further cases of Tetralogy of Fallot were diagnosed during the first week of life.

A case of Beckwith-Wiedemann syndrome with macroglossia and a non-neoplastic naevus but without exomphalos was diagnosed. This condition may often present with neonatal hypoglycaemia.

## 2.3. Between 1-4 weeks

Overall 16 cases are recorded as being diagnosed with 1 and 4 weeks.

Approximately one third of cases, (n=5), were cardiac in origin. Coarctation of the aorta was seen in two cases and pulmonary valve stenosis in three.

Typically 'Endocrine and Metabolic' disorders are still being diagnosed as a consequence of the Newborn Blood Spot programme, yet in this review only one case of congenital hypothyroidism is added to the list.

Other abnormalities included Prader Willi syndrome, achondroplasia, septo-optic dysplasia and two cases of congenital cataracts.

Aplasia cutis was diagnosed within the first few weeks of life in one case. This is a condition with congenital absence of an area of skin. It is typically seen in association with Trisomy 13, Wolff-Hirschhorn syndrome and following exposure to methimazole and carbimazole. Unfortunately no maternal history is available.<sup>4</sup>

## 2.4. Diagnosed after 1 month but within 1 year

There were a total of 34 cases in which the primary abnormality was diagnosed after 1 month but within 1 year, (Figure 2.4). The majority, (n=10), were disorders of the 'Cardiac and Circulatory System' including a further case of Tetralogy of Fallot. Persistent patent ductus arteriosus is, of course, a common diagnosis at this stage with five cases seen.

The eight cases classified as disorders of the musculoskeletal syndrome were predominately those of congenital deformity of the hip in female infants, (n=6), but two cases of craniosynostosis were also described.

A case of Rett Syndrome, (see later), was diagnosed after one month in a female infant with microcephaly.

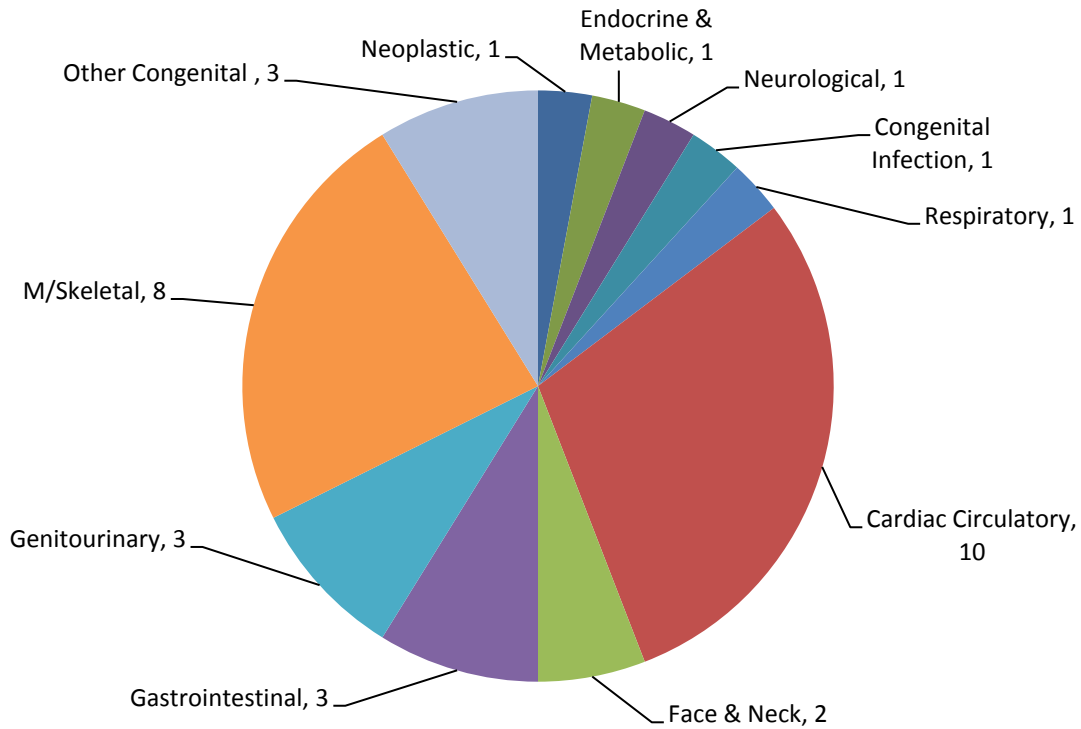
Other 'late' diagnoses included biliary atresia, cystic fibrosis, William's Syndrome, Tuberous Sclerosis and Pierre Robin Sequence

The diagnosis of congenital pneumonia would appear to have been a little delayed.

---

<sup>4</sup> Data on 'maternal exposure' are no longer collected. Lack of resources has considerably reduced the data set.

**Figure 2.4: Diagnosis after 1 month but within 1 year by Primary Abnormality (ICD10), (n=34)**



### 2.5. Diagnosis after 12 months

The data set for the 2012-2013 continues to develop and evolve as further diagnoses are made. Two 'late' diagnoses of fetal abnormality are described in the current data.

Q031	DANDY WALKER COMPLEX	Male; Live-birth @ term
Q630	DUPLEX KIDNEY (L)	Female; Live-birth @36 wks

Dandy Walker syndrome is associated with hydrocephalus, partial or complete absence of the cerebellum and a posterior fossa cyst contiguous with the 4<sup>th</sup> ventricle. These abnormalities are usually diagnosed on antenatal scan or when cerebellar signs become apparent in early neonatal life. However in some 10-20% of cases the clinical features do not develop until late childhood or early adulthood. Case reports have been published of this diagnosis being recorded for the first time in elderly patients hospitalized for gait disorders or recurrent falls

Further diagnoses will continue to be made and this data set will increase over and above that presented in this current report.

### 2.6. Prenatal Diagnosis

The majority of primary abnormalities were diagnosed during the antenatal period, (n=173), (Figure 2.5).

Thirty-five cases were associated with chromosomal abnormality of which the majority, (n=13), were Down syndrome, (Trisomy 21). There were also 12 cases of Trisomy 18, 4 cases of Trisomy 13, and 3 cases of Triploidy. Turner's syndrome (45, XO) was seen in 2 cases and Klinefelter's syndrome in one case.

The neoplastic diagnoses were all congenital lymphangioma/cystic hygroma. Of the 17 cases of gastrointestinal abnormality, 76.5% (n=13), were defects of the anterior abdominal wall. Renal agenesis, either unilateral or bilateral, was an antenatal diagnosis on 9 occasions. The remarkable prenatal diagnosis of hypospadias has already been explained.

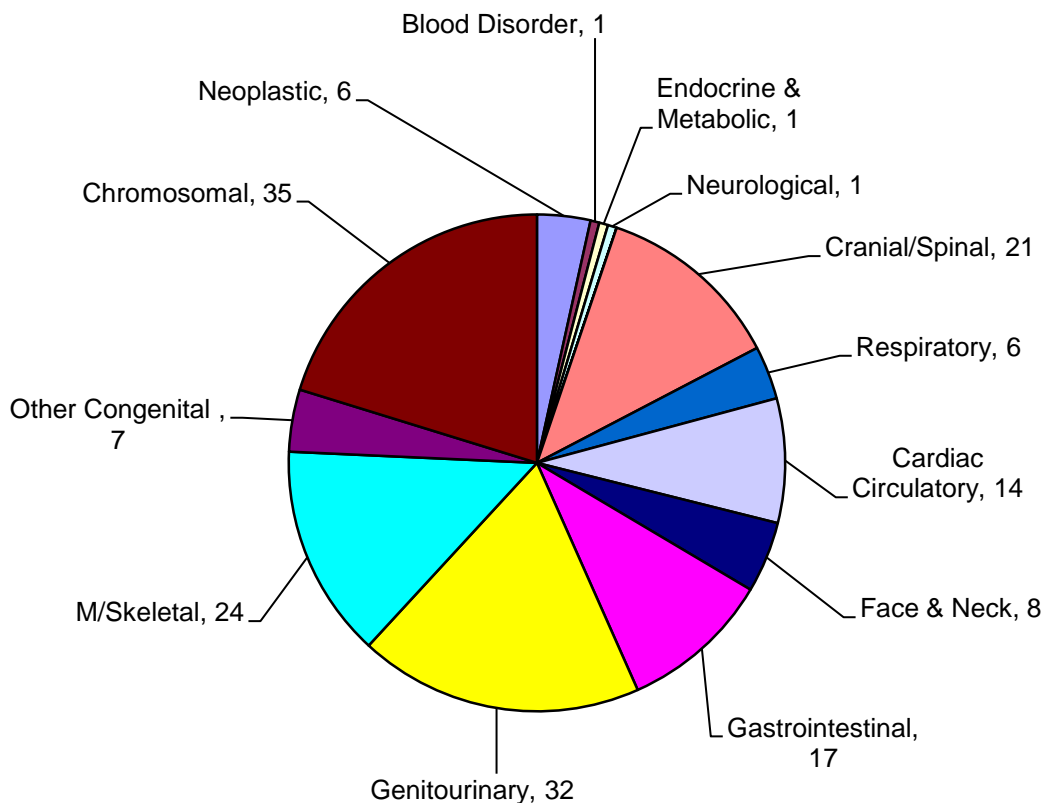
Neural tube defects, (spina bifida, anencephaly and encephalocele), account for 50% of cranial and spinal lesions diagnosed on antenatal ultrasound. Three cases of hydrocephalus and 2 cases of holoprosencephaly were also detected.

Eight cases of cleft lip, (with or without an associated cleft palate), were detected on prenatal ultrasound scan.

Cardiac and circulatory disorders diagnosed on antenatal scan included hypoplastic left heart, (n=6), Tetralogy of Fallot, (n=1), and Coarctation of the aorta,(n=2).

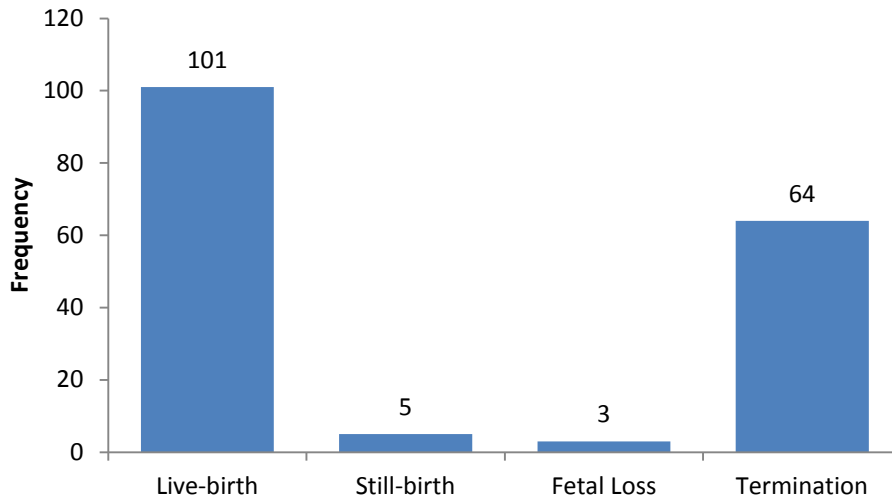
Fifty-eight percent of musculoskeletal disorders detected on ultrasound were talipes equino-varus, (n=14). Three cases of osteogenesis imperfecta were detected on prenatal assessment.

**Figure 2.5: Prenatal Diagnosis by Primary Abnormality (ICD10), (n=173).**



Where a prenatal diagnosis of abnormality was made sixty-four cases were terminated, (37%), but in the majority of cases, (n=101; 58.4%) the pregnancy continued to live-birth. Eight cases, (4.6%), were either stillborn or a spontaneous fetal loss, (Figure 2.6).

**Figure 2.6: Outcome of pregnancies in which there was prenatal diagnosis of abnormality, (n=173).**



### 2.7. Unknown

There were 5 cases in which the point of diagnosis is recorded as ‘unknown’. Four cases were live born. One case associated, with exomphalos and lymphangioma, was a late fetal loss at 21 weeks gestation and may be related to an underlying chromosomal abnormality. With the exception of the latter case it is likely that diagnosis of abnormality was made soon after birth, (Table 2.1).

**Table 2.1: Cases in which Point of Diagnosis is ‘Unknown’, (n=5).**

H903	CONGENITAL SENSORINEURAL DEAFNESS	Live-birth @ term
Q120	CATARACT-BILATERAL	Live-birth @ term
Q660	TALIPES EQUINO VARUS ®	Live-birth @ 28 weeks
Q792	OMPHALOCOELE	Fetal loss @ 21 weeks; Lymphangioma
Q825	LARGE BIRTHMARK	Live-birth @ term

### 2.8. Post-mortem

There were only four cases where the diagnosis has been recorded as having been made at post-mortem, (Table 2.2). Clearly a good many of the diagnoses reported were actually diagnosed at post-mortem but the ‘date of discovery’ does not necessarily imply the stage at which a primary diagnosis is actually made – just the point at which an anomaly is suspected. The mean gestational age at time of loss or delivery was 26.5 weeks.

**Table 2.2: Cases diagnosed at post mortem.**

Q201	DOUBLE OUTLET RIGHT VENTRICLE	Fetal loss @ 20 weeks; Single umbilical artery
Q213	TETRALOGY OF FALLOT	Stillbirth @ 30 weeks
Q7980	AMNIOTIC BAND SEQUENCE	Fetal loss @ 20 weeks
Q980	KLINFELTER’S	Stillbirth @ 36 weeks

### 3. Pregnancy Outcome

A pregnancy outcome is recorded for all 365 cases. The majority of cases were live-born, (Figure 3.1 and Figure 3.2).

Figure 3.1: Pregnancy Outcome, (n=365).

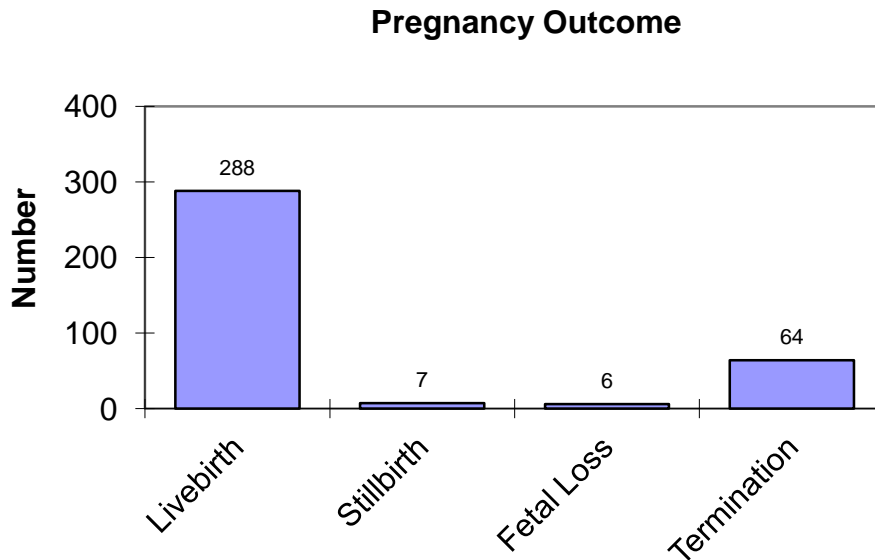
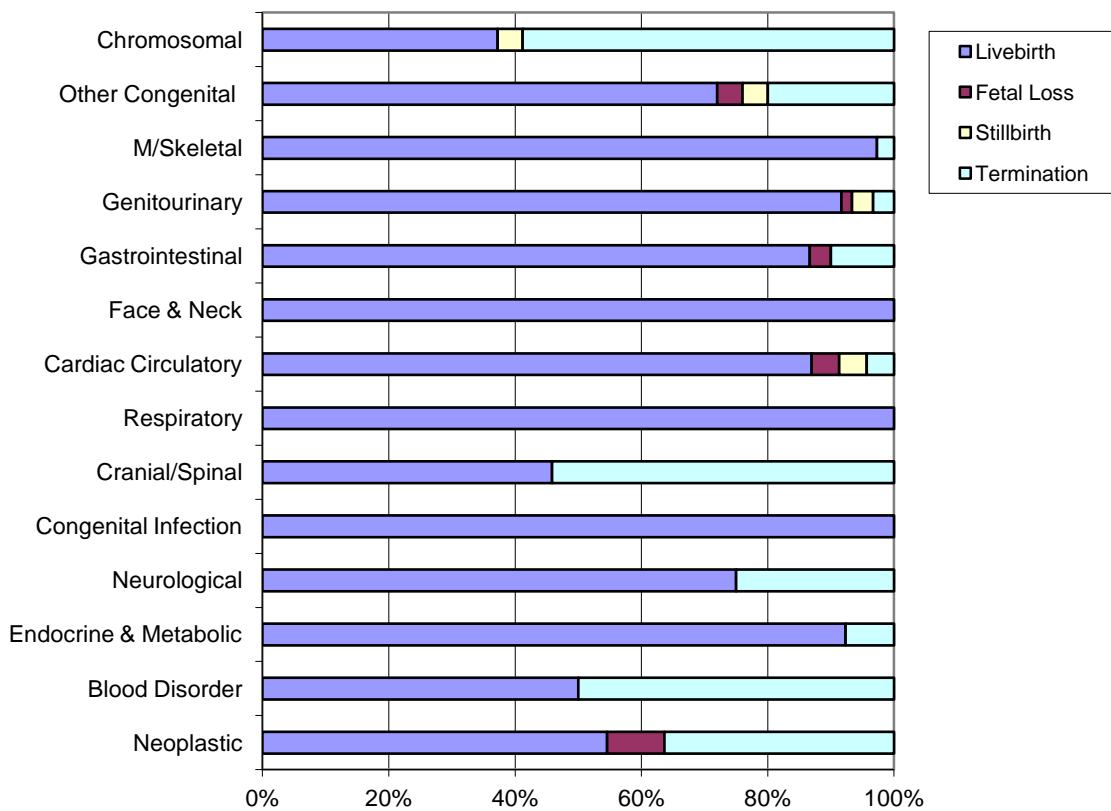


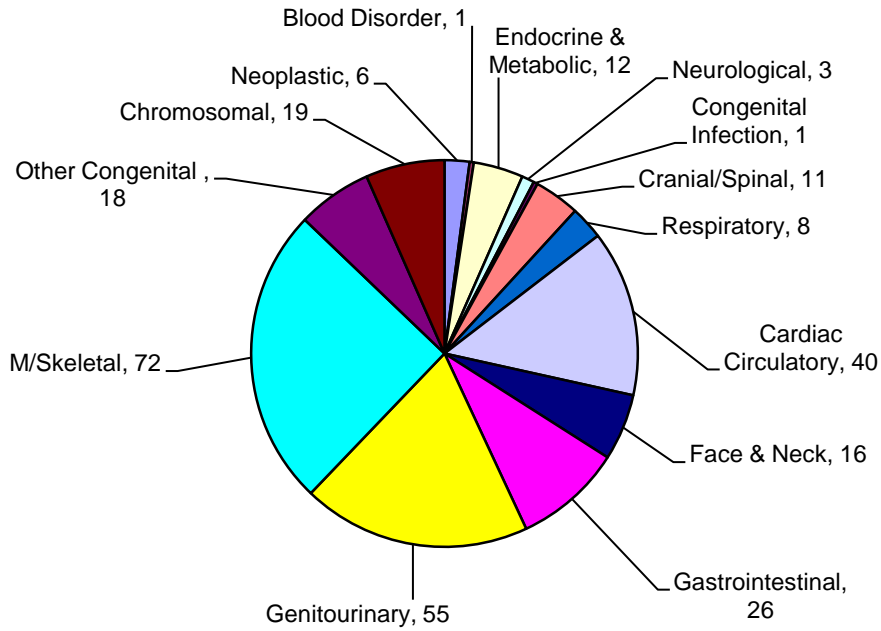
Figure 3.2: Outcome by simplified classification, (n=365).



### 3.1. Live-birth

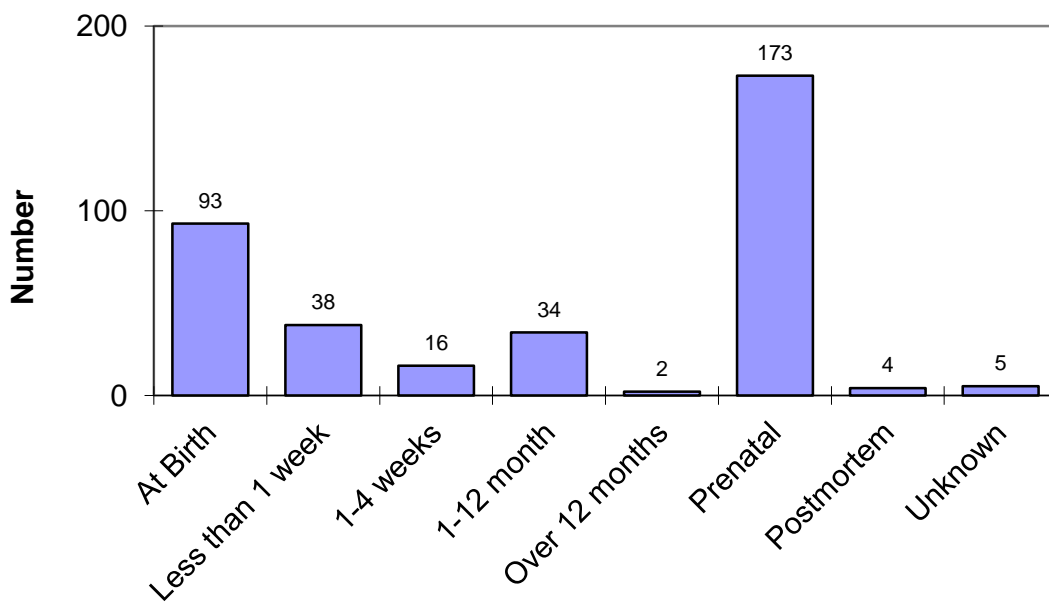
Live-birth was the documented outcome for 78.9% of cases, (n=288), (Figure 3.3).

**Figure 3.3: Live-birth by Primary Abnormality, (n=288)**



Diagnosis was made at birth for 32.3% of cases, (n=93), (Figure 3.4). Prenatal diagnosis was achieved for 60%, (n=173).

**Figure 3.4: Point of Diagnosis of Primary Abnormality for Live-births, (n=288)**



### 3.2. Stillbirth

The data records seven stillbirths with a defined abnormality during the study period. Mean gestation at delivery was 31.1 weeks. In five cases the primary abnormality was diagnosed on antenatal ultrasound scan. The remaining cases were one of Klinefelter syndrome and another of Tetralogy of Fallot. In both cases the diagnosis was made at post-mortem.

Q213	TETRALOGY OF FALLOT	Stillbirth @ 30 weeks; Post-mortem diagnosis
Q2542	AORTIC VALVE OVERRIDES VSD	Prenatal diagnosis;
Q602	RENAL AGENESIS	Prenatal diagnosis;
Q611	POLYCYSTIC KIDNEY DISEASE	Prenatal diagnosis;
Q8980	CAUDAL REGRESSION SEQUENCE	Prenatal diagnosis;
Q910	TRISOMY 18	Prenatal diagnosis;
Q980	KLINFELTER SYNDROME	Stillbirth @ 36 weeks; Post-mortem diagnosis

### 3.3. Spontaneous Fetal Loss

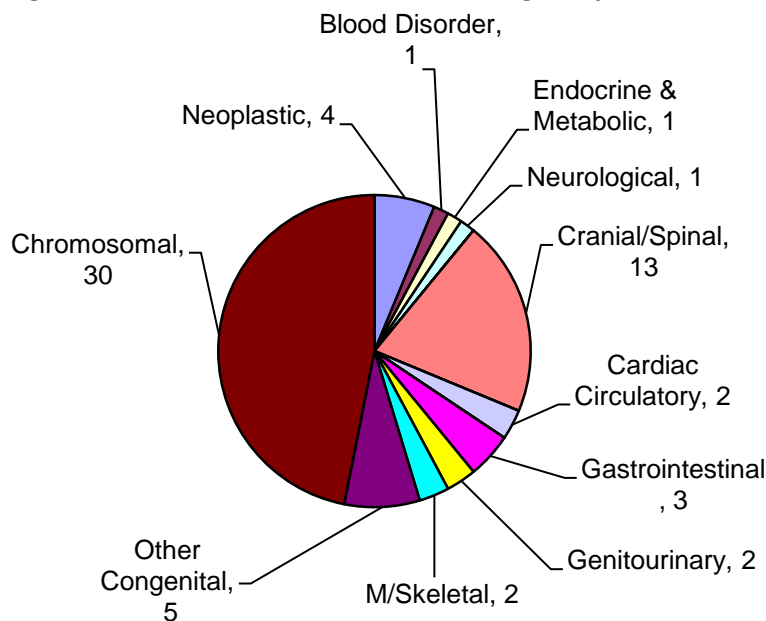
There were six fetal losses recorded in the 2012-2013 data. Previous reviews have documented a high proportion of chromosomal abnormalities in this group. However on this occasion it is much more heterogenous. Mean gestation at loss was 17.5 weeks

D1810	CYSTIC HYGROMA	Prenatal diagnosis
Q201	DOUBLE OUTLET ® VENTRICLE	Single Umbilical Artery
Q213	TETRALOGY OF FALLOT	Prenatal diagnosis; Multiple abnormalities
Q643	BLADDER OUTLET OBSTRUCTION	Prenatal diagnosis; Congenital phlebectasia
Q792	EXOMPHALOS	Cystic hygroma
Q7980	AMNIOTIC BAND SEQUENCE	Post-mortem diagnosis

### 3.4. Termination of Pregnancy

A total of sixty-four cases were terminated following prenatal diagnosis, (Figure 3.5). The mean gestation at termination was 16.3 weeks, (range 11 to 23 weeks).

**Figure 3.5: Diagnostic indication for Termination of Pregnancy, (ICD10), (n=64)**



Chromosomal abnormality was the commonest indication for termination, (n=30), followed by neural tube defects and other cranial and spinal abnormalities, (n=14). The number of cases in each

of the other categories was small. The lesions classified as 'Neoplastic' were all isolated congenital cavernous lymphangionas, (cystic hygroma). Two cases of bilateral renal agenesis were terminated. A variety of disorders classified as 'Other Congenital' were terminated. These included Amniotic Band sequence, VATER association, Caudal Regression sequence and oro-facial digital syndrome.

VATER/VACTERL is a non-random association of birth defects that affects multiple organ systems. The term VACTERL is an acronym where V=vertebral abnormality; A=anal atresia; C=cardiac defects; T=tracheal anomalies including tracheo-oesophageal fistula; E=oesophageal atresia; R=renal and /or radial abnormality and L= other limb abnormalities. In addition affected children may also exhibit growth deficiencies but mental functioning and intelligence are usually unaffected. The exact cause of VATER/VACTERL association is unknown with most cases being sporadic.

Oro-facial-digital syndrome is also a group of related conditions that affect the development of the oral cavity, facial features and digits. There are at least 13 potential forms of oro-facial-digital syndrome. The different types are classified by their patterns of signs and symptoms, (which may vary widely). The most common form, Type 1, is associated with polycystic kidney disease and is due to a mutation in the *OFD1* gene. Type 1 oro-facial digital syndrome is inherited in an X-linked dominant pattern. The classification system continues to evolve. However, most forms are also associated with some degree of intellectual disability.

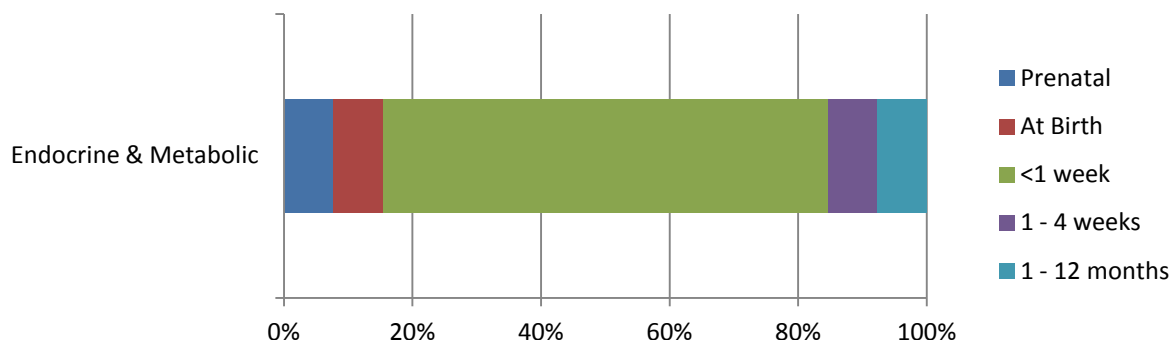


## 4. Review by Defined Abnormality

### 4.1. Endocrine & Metabolic Disorders

These disorders are typically diagnosed as a consequence of Newborn Bloodspot screening within the first few weeks of life, (Figure 4.1).

**Figure 4.1: Point of Diagnosis: Endocrine & Metabolic Disorders, (n=13).**



#### 4.1.1. In-born Errors of Metabolism

##### G6PD Deficiency (D550)

This is an X-linked recessive hereditary disorder characterized by low levels of glucose-6 phosphate dehydrogenase, (G6PD). Glucose-6 phosphate dehydrogenase is an important enzyme in red cells as well as leucocytes and other cells. Deficiency of this enzyme makes red cells liable to haemolyse in certain situations and the disorder may present with neonatal jaundice or haemolytic crisis.

D550 G6PD DEFICIENCY Male infant; Diagnosed at birth

##### 21-Hydroxylase Deficiency, (E2500)

This disorder is usually diagnosed on newborn screening but can present with genital ambiguity as a consequence of virilization of female infants

E2500 21 HYDROXYLASE DEFICIENCY Female infant; Live birth @ 37 wks;

##### Adrenoleukodystrophy, (ALD), (E713)

This is a disorder of peroxisomal fatty-acid beta oxidation. ALD leads to the accumulation of very long-chain fatty-acids, (particularly cerotic acid), which are typically deposited within the CNS, the adrenal cortex and Leydig cells in the testis. It is an X-linked disorder. ALD is due to a mutation in ABCD1, a peroxisomal membrane transport protein located on the X chromosome. It occurs in 1:20,000 live births and is the most common peroxisomal inborn error of metabolism.

E713 ADRENOLEUKODYSTROPHY Prenatal diagnosis; Termination @ 17wks

The disorder is widely known through the film story of 'Lorenzo's Oil', a true account of a relentless search conducted by two parents, Augusto & Michaela Odone, for a therapeutic cure for their son Lorenzo.

#### 4.1.2. Congenital Hypothyroidism, (E0310; E0312; E039)

Congenital hypothyroidism can be the result of a missing or 'misplaced' thyroid gland, hereditary, maternal iodine deficiency and maternal thyroid conditions and medication. Four cases of congenital hypothyroidism are described. All were live births.

E0310	CONGENITAL HYPOTHYROIDISM	Diagnosed < 1 week of life
E0312	CONGENITAL HYPOTHYROIDISM	Diagnosed < 1 week of life
E039	CONGENITAL HYPOTHYROIDISM	Preterm birth @ 28 wks; Diagnosed < 1 week of life
E039	CONGENITAL HYPOTHYROIDISM	Diagnosed 1 - 4 weeks of life

### **Pendred Syndrome**

Pendred Syndrome is a genetic disorder leading to congenital bilateral sensorineural hearing loss and goitre with occasional hypothyroidism.

E071	PENDRED SYNDROME	Livebirth @ 38 wks; Congenital deafness
------	------------------	---

There is no specific treatment, other than supportive measures for the hearing loss and thyroid hormone supplementation in cases of hypothyroidism. The syndrome is named after Dr Vaughan Pendred, (1869–1946), who first described the condition in an Irish family living in Durham in 1896. Pendred Syndrome accounts for 7.5% of all cases of congenital deafness. In this case diagnosis was made during the first week of life.

#### **4.1.3. Cystic Fibrosis, (E840; E841; E849)**

Approximately 1:2,500 babies born in the UK have cystic fibrosis. There were five cases of cystic fibrosis diagnosed in 2012-2013 giving an NHS GG&C incidence of 1:3171 maternities. All were live births. There were no associated abnormalities.

E840	CYSTIC FIBROSIS	Diagnosed < 1 week of life
E840	CYSTIC FIBROSIS	Diagnosed < 1 week of life
E840	CYSTIC FIBROSIS	Diagnosed after 1 month
E840	CYSTIC FIBROSIS	Diagnosed < 1 week of life
E849	CYSTIC FIBROSIS	Diagnosed < 1 week of life

#### **4.1.4. Other Metabolic**

##### **Hypopituitarism, (E230)**

Hypopituitarism was seen in association with Septo-optic dysplasia.

Q044	SEPTO-OPTIC DYSPLASIA	Live-birth @ 37 weeks
------	-----------------------	-----------------------

Septo-optic dysplasia is one of the commonest of the midline cerebral/cranial abnormalities, (a spectrum of disorders that include holoprosencephaly, absence of the corpus callosum and midline cleft palate). There is optic nerve hypoplasia, absence of the septum pellucidum and pituitary dysfunction. The pituitary dysfunction is often variable. It has the unusual characteristic of being commonly associated with diabetes insipidus as well as anterior pituitary dysfunction. Anterior pituitary function may 'evolve' with time and can be associated with a retention of ability for gonadotrophin secretion with either normal or precocious puberty.

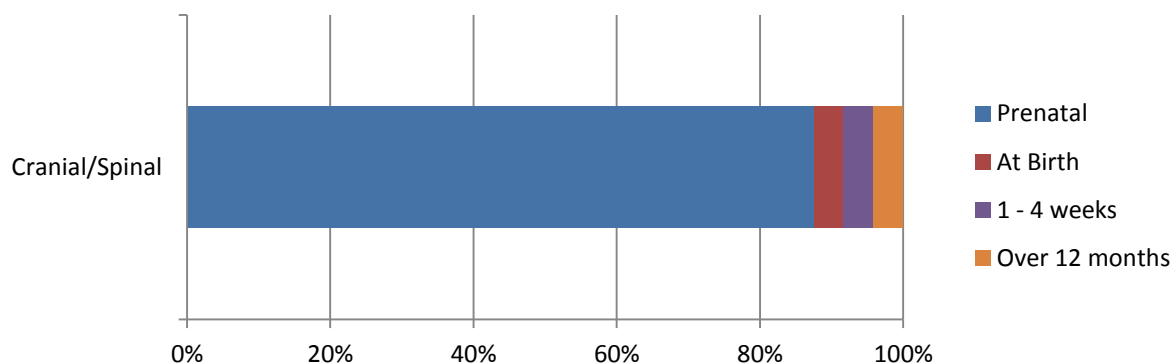
NOTE:-

Unusually there were no cases of Phenylketonuria, (PKU), or Medium-chain acyl-dehydrogenase deficiency, (MCADD) diagnosed within NHS GG&C during 2012-2013.

## 4.2. Cranial & Spinal Abnormalities

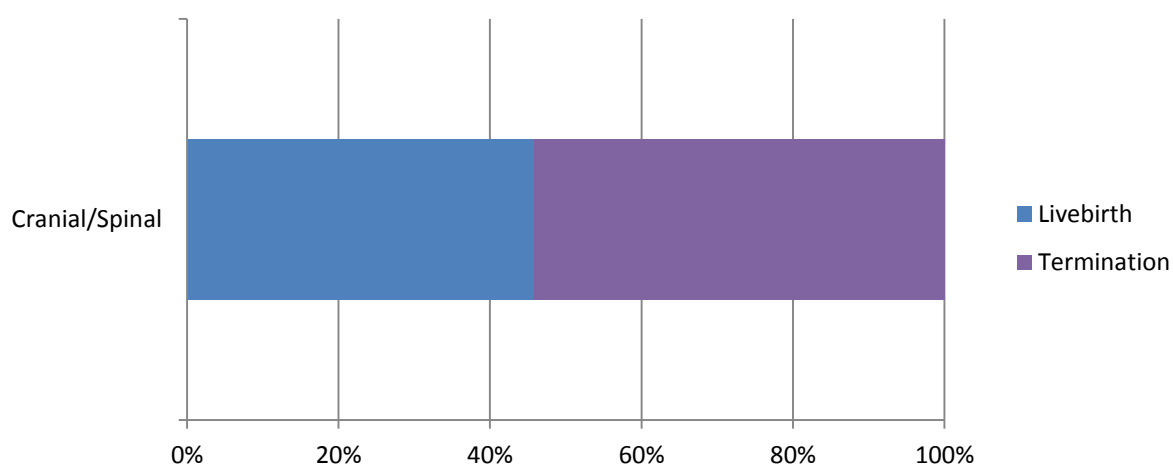
Eighty percent, (n=24), of all diagnoses of cranial & spinal abnormality appear in the primary position. Nearly eighty-eight percent, (n=21), of all primary 'Cranial & Spinal' abnormalities are diagnosed antenatally, (Figure 4.2).

**Figure 4.2: Point of Diagnosis of Primary Cranial & Spinal Abnormality**



Most pregnancies with a primary diagnosis of cranial spinal abnormality ended in termination following prenatal diagnosis, (Figure 4.3)

**Figure 4.3: Outcome of Pregnancy with Primary Cranial & Spinal Abnormality**



### 4.2.1. Neural Tube Defect, (NTD)

Neural Tube Defects are malformations of the brain and spinal cord. The clinical spectrum includes anencephaly, encephalocele, craniorachischisis, hydranencephaly, iniencephaly, spina bifida cystica and spina bifida occulta.

#### Anencephaly, Acrania & Exencephaly, (Q000)

There were 3 cases of anencephaly/exencephaly. They are all listed in the primary position, (there are no cases listed in the secondary position), and were all evident on prenatal scan. One case was associated with an unspecified malformation of the peripheral vascular system, (Q278).

Q000	ANENCEPHALY	Termination @ 17 weeks gestation
Q000	ANENCEPHALY	Termination @13 weeks gestation
Q000	ANENCEPHALY	Termination @ 11 weeks gestation

**Encephalocoele, (Q010, Q012, Q019)**

One case of encephalocoele was diagnosed on prenatal scan and listed in the primary diagnostic position. There were a number of associated features included reduction defects of upper and lower limbs, (the fibula in particular), and radial 'club-hand'.

Q019      ENCEPHALOCOELE                      Termination @ 15 weeks gestation

Occipital encephalocoele was also seen in association with holoprosencephaly, (see below).

**Spina Bifida, (Q0511, Q0521, Q0531, Q055, Q0572, Q0582, Q059)**

A total of seven cases of spina bifida are listed. There were 6 cases where spina bifida is recorded as the primary abnormality.

Q051	T/L MYELOMENINGOCOELE	Arnold-Chiari Malformation
Q0511	THORACIC MYELOMENINGOCOELE	Arnold-Chiari Malformation; Ectopic kidney
Q052	L/S SPINA BIFIDA	Hydrocephalus
Q052	L/S SPINA BIFIDA	Arnold-Chiari Malformation
Q0521	L/S SPINA BIFIDA - OPEN	Arnold-Chiari Malformation; ASD
Q054	MYELOMENINGOCOELE - LARGE	Arnold-Chiari Malformation

Spina Bifida is also recorded as a secondary diagnosis in one further case.

Q8980      CAUDAL REGRESSION SEQUENCE                      Lumbar Spina bifida without hydrocephalus

All diagnoses of spina bifida were made on prenatal ultrasound scan. Two pregnancies continued to live-birth at 38-39 weeks gestation following prenatal diagnosis. In four cases termination of pregnancy was performed. The case of caudal regression sequence was a stillbirth at 25 weeks gestation.

**4.2.2. Holoprosencephaly, (Q042)**

This is a condition in which only a single large ventricle is seen or with a small skull containing no midline echo, disorganized cerebral ventricles and prominent cerebral peduncles. The disorder is associated with chromosomal defects, typically Trisomy 13. Holoprosencephaly was recorded as a primary abnormality in two cases; both were diagnosed on prenatal ultrasound and terminated.

Q042	HOLOPROSENCEPHALY	Triploidy; Malformation of skull
Q042	HOLOPROSENCEPHALY	Occipital encephalocoele

Holoprosencephaly was also seen as a secondary diagnosis with Trisomy 13. Associated features included exomphalos and a proboscis.

Q914      TRISOMY 13                                      Prenatal diagnosis; Termination

**4.2.3. Microcephaly, (Q02X)**

Microcephaly is associated with many causes and usually results in severe mental retardation. Diagnosis does not usually become apparent until the end of the second trimester when there is a reduction in brain growth leading to corresponding decrease in head size. Therefore diagnosis at the time of the routine anomaly scan is unlikely. Causes include CNS malformations, infections (CMV, rubella, and toxoplasmosis), chromosomal abnormalities, maternal PKU and certain teratogens.

There were four cases of microcephaly. In three cases microcephaly is the primary diagnosis in the remaining case it is an associated feature of Rett Syndrome.

Q02X	MICROCEPHALY	Live-birth; Diagnosis at birth; Ectopic anus
Q02X	MICROCEPHALY	Live-birth; Prenatal diagnosis
Q02X	MICROCEPHALY	Terminations; Prenatal diagnosis; Medial facial defect
F842	RETT SYNDROME	Live-birth @ 39 weeks; Diagnosed after 1 month

Rett Syndrome is the clinical expression of the Rett disorder a complex genetic neurological condition. The Rett disorder affects more than 1:10,000 females and considerably fewer males> most cases are sporadic. The cause of Rett syndrome is a mutation of a gene, MECP2 on the X-chromosome. Individuals with Rett syndrome are always profoundly disabled.

#### 4.2.4. Hydrocephalus, (Q030, Q039)

Three cases of hydrocephalus are listed in the primary diagnostic position. All cases were diagnosed on antenatal ultrasound scan and all but one case were associated with other abnormalities.

Q039	HYDROCEPHALUS	Live-birth
Q039	HYDROCEPHALUS	Live-birth; Absent septum pellucidum
Q039	HYDROCEPHALUS	Termination;

#### 4.2.5. Other Cranial & Spinal Abnormalities

##### Agnesis of the Corpus Callosum, (Q0400)

The true frequency with which the corpus callosum fails to form is not known. There may well be asymptomatic individuals with partial or complete callosal agnesis. Agnesis of the Corpus Callosum, (ACC), is commonly associated with other abnormalities. It is the primary diagnosis in only one case. Aicardi syndrome, characterized by the partial or complete absence of the corpus callosum, is only observed in girls or boys with Klinefelter syndrome.

Q0400	AICARDI SYNDROME	Prenatal diagnosis; Live-birth; Female; Coloboma
-------	------------------	--

Agnesis of the Corpus Callosum is a secondary diagnosis in four further cases.

Q043	ABSENT SEPTUM PELLUCIDUM	Prenatal diagnosis; Live-birth; Female
Q0511	THORACIC MYELOMENINGOCOELE	Arnold-Chiari Malformation; Ectopic kidney
Q700	ACROSYNDACTYLY-BILAT	Live-birth; Hypospadias
Q8707	ORO-FACIAL-DIGITAL	Cerebral cysts; Webbed fingers; Cleft lip & palate

The case of open thoracic myelomeningocoele with hydrocephalus, ectopic kidney and absent corpus callosum, was a live birth at 38 weeks gestation following prenatal diagnosis.

The case of oro-facial-digital syndrome was terminated following prenatal diagnosis at 21 weeks, (see earlier).

NOTE: -

Malformations such as congenital spondylolisthesis and hemivertebral syndromes, (but not spina bifida occulta), are classified under 'Congenital disorders of the Musculoskeletal System'.

### 4.3. Cardiac & Circulatory

Disorders of the 'Heart & Circulatory System' are the second most common grouping of defined abnormalities, (n=99, 17.1%), and 46.5% of these abnormalities are in the primary diagnostic position, (46/99).

The commonest listed abnormality, (in any position), of the 'Cardiac and Circulatory' system was Ventricular Septal defect, (n=18).

The severest forms of Congenital Heart Disease (CHD) should be identifiable on prenatal ultrasound scan by 24 weeks gestation. The classic 'four-chamber view' will diagnose the majority but certainly not all of these abnormalities. Additional views including visualization of both Left and Right Outflow Tracts are recommended to improve diagnostic ascertainment.<sup>5</sup>

At this point it is probably relevant to introduce 'EUROCAT', the European Surveillance of Congenital Anomalies. In practice this is a study based on a network of population based registries for the epidemiological surveillance of congenital anomalies. It was started in 1979 and surveys more than 1.7M births per year in Europe.

As part of the review process EUROCAT defines a list of Severe Congenital Heart Defects, (Table 4.1). These, in essence, are those cardiac malformations that require surgical resolution. Overall thirty-four cases displayed thirty-five abnormalities that would fulfil the EUROCAT criteria for Severe Congenital Heart Disease.

**Table 4.1: EUROCAT Severe Congenital Heart Disease**

Common arterial truncus (Q200)	No cases;
Transposition of Great arteries (Q203)	2 cases;
Single ventricle (Q204)	No cases;
Atrioventricular septal defect (Q212)	3 cases, (all as 2ndry diagnosis);‡
Tetralogy of Fallot (Q213)	7 cases;
Tricuspid Atresia & Stenosis (Q224)	No cases;
Ebstein's anomaly (Q225)	2 cases;
Pulmonary valve atresia (Q220, Q221)	5 cases, (one as a 2ndry diagnosis);
Aortic valve atresia/stenosis (Q230)	1 case;
Hypoplastic left heart (Q234, Q248)	5 cases;
Hypoplastic right heart (Q226)	1 case; *
Coarctation of aorta (Q251)	7 cases;
Total anomalous pulmonary venous return (Q262)	2 cases;

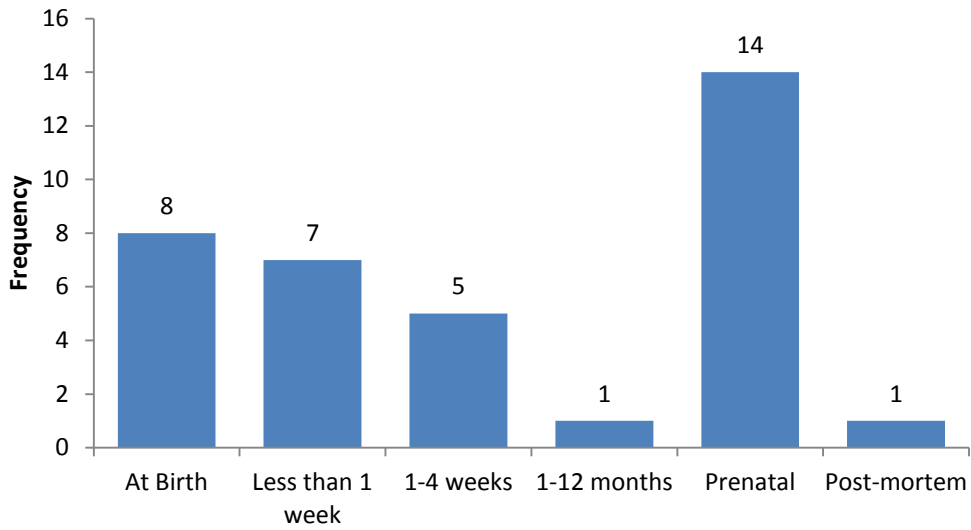
‡The three cases of atrioventricular septal defect were all associated with Down Syndrome.

\*The case of Hypoplastic Right Heart was associated with Pulmonary Valve Atresia with both these abnormalities and a co-existing VSD diagnosed on prenatal scan.

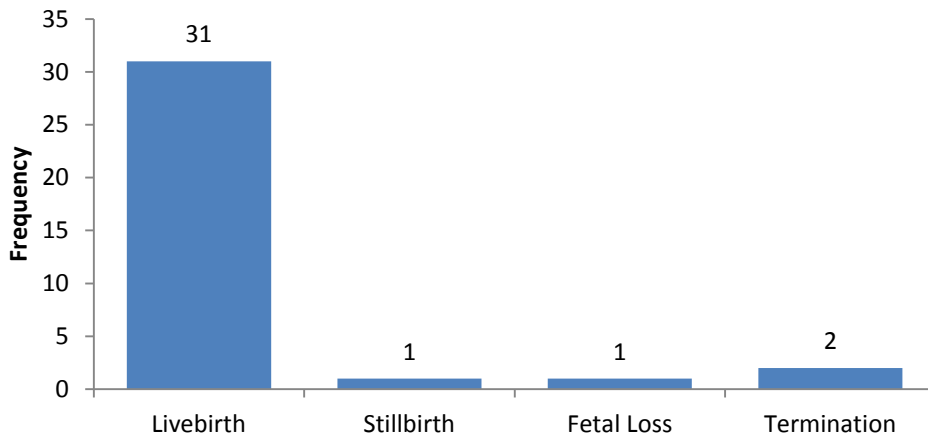
Of these thirty-five abnormalities only fourteen were diagnosed on prenatal ultrasound scan, (Figure 4.3). Antenatal detection rate for EUROCAT defined Severe Cardiac Abnormality would therefore appear to be poor at just 40%, (expected detection rate of 50%). The majority of cases were live born, (Figure 4.4).

<sup>5</sup> NSC Recommendations.

**Figure 4.3: Point of Diagnosis of EUROCAT defined Severe Cardiac Abnormality, (n=35).**

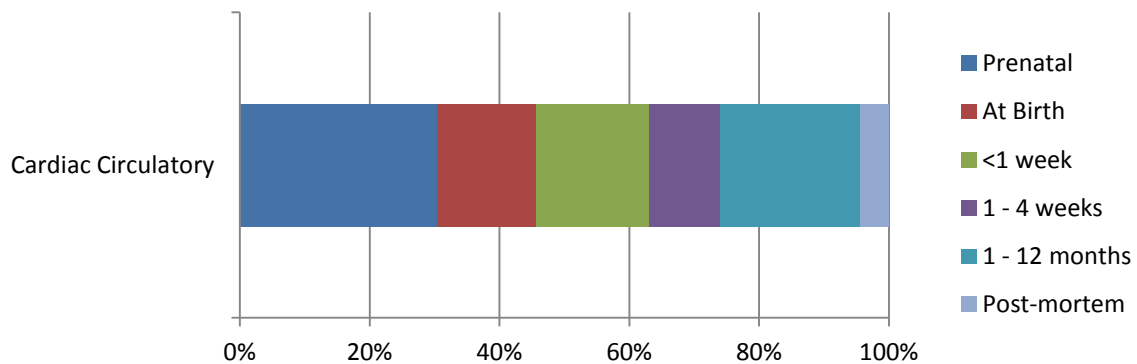


**Figure 4.4: Outcome of pregnancies associated with EUROCAT defined Severe Cardiac Abnormality, (n=35).**



However, looking at the data overall and not just the Severe Cardiac Abnormalities, the majority of primary cardiovascular abnormalities were diagnosed within the first 4 weeks of life, (n=20, 43%). However 30%, (n=14), were diagnosed on prenatal scan, (Figure 4.5).

**Figure 4.5: Point of diagnosis of primary cardiac abnormalities, (n=46)**



Clearly a number of diagnoses of primary cardiac abnormality are not made until 1 - 12 months of age, (n=10, 22%). Five of these were cases of Patent Ductus Arteriosus (PDA). One case of Tetralogy of Fallot was not diagnosed until after 1 month. There was also a case of 'Other Congenital Abnormality of the Great Vessels', (or more accurately an aberrant left coronary artery). The remainder were atrial, (n=2), and ventricular, (n=1), septal defects.

#### 4.3.1. Hypoplastic Left Heart Syndrome, (Q234, Q248)

In these cases the left ventricle is under-developed. The abnormality is frequently associated with hypoplasia or atresia of the mitral valve, aortic valve and arch of the aorta. Typically quoted at an incidence of 0.2/1000 live-births, (0.02%). Hypoplastic left heart accounts for 7-9% of all cases of congenital heart disease diagnosed during the first year of life.

Five cases of hypoplastic left heart syndrome, (Q234), were diagnosed in NHS GG&C during 2012-2013. One case was seen in a 2<sup>nd</sup> twin, the co-twin showed no sign of abnormality. The majority of diagnoses, (n=4 and including that in the twin), were made on prenatal scan with the mother electing to continue with the pregnancy. In the remaining case, associated with Congenital Mitral Stenosis, the diagnosis was made at birth.

Q234	HYPOPLASTIC LEFT HEART	Live-birth @ 39 weeks
Q234	HYPOPLASTIC LEFT HEART	Live-birth @ 33 weeks; 2nd twin
Q234	HYPOPLASTIC LEFT HEART	Live-birth @ 40 weeks
Q234	HYPOPLASTIC LEFT HEART	Live-birth @ 39 weeks
Q234	HYPOPLASTIC LEFT HEART	Live-birth @ 37 weeks; Congenital Mitral stenosis

A further case classified as '(L) Side of Heart Smaller than Right', (Q248), was a prenatal diagnosis that was associated with cerebral cysts and other unspecified congenital malformation of the fetal brain. Termination of pregnancy was performed at 22 weeks gestation.

Q248	(L) HEART SMALLER THAN RIGHT	Termination of Pregnancy; Cranial Abnormalities
------	------------------------------	---

Yet it is uncertain if this really does imply a hypoplastic left heart. This ICD10 coding is weak and was used to define a malposition of the heart in a further three cases.

Q220	SMALL ATRETIC PULMONARY VALVE	Prenatal diagnosis; Termination
Q225	EBSTEIN'S ANOMALY - SEVERE	Live-birth @ term
Q914	TRISOMY 13	Prenatal diagnosis; Termination

#### 4.3.2. Transposition of the Great Vessels, (Q203)

This abnormality results from an abnormal division of the truncus arteriosus. In transposition the septum dividing the truncus has failed to rotate so that the aorta arises from the right ventricle and the pulmonary artery from the left. This leads to two independent circulations and would be incompatible with ex-utero life if it wasn't for the fact that there is nearly always a communication in the form of ASD, VSD or PDA. Extra-cardiac abnormalities are rare and prognosis is generally good.

There were two cases, both live born, where Transposition of the Great Vessels is recorded as the primary abnormality.

Q203	TGA	Male; Live-birth; Diagnosed at birth;
Q203	TGA	Male; Live-birth; Diagnosed < 1 week;



#### 4.3.3. Fallot's Tetralogy, (Q213)

Fallot's Tetralogy is a single error of development with four consequences. The septum dividing the truncus instead of joining up with the inter-ventricular septum deviates to the right. The right ventricular outflow is therefore restricted, (pulmonary stenosis or atresia), the aorta extends to the right of the septum, (over-riding aorta), and receives blood from both ventricles and there is a deficiency in the upper part of the membranous septum, (VSD). The right ventricle hypertrophies to pump blood through both a narrowed pulmonary orifice and the aorta.

Seven cases of Fallot's Tetralogy are listed in the 2012-2013 data with the abnormality always recorded in the primary position. In comparison there were just two cases of Fallot's Tetralogy identified in the 2010-2011 review and only a single case in 2011-2012.

Q213	TETRALOGY OF FALLOT	Live-birth@ term; Diagnosis < 1 week
Q213	TETRALOGY OF FALLOT	Live-birth @ term; Diagnosis made after 1 month
Q213	TETRALOGY OF FALLOT	Stillbirth @ 30 weeks; Diagnosis at post-mortem
Q213	TETRALOGY OF FALLOT	Live-birth@ term; Diagnosis < 1 week
Q213	TETRALOGY OF FALLOT	Live-birth@ term; Diagnosis < 1 week
Q213	TETRALOGY OF FALLOT	Congenital malformation of aorta; VSD; Diagnosis at birth
Q213	TETRALOGY OF FALLOT	Fetal loss; Malformation of bladder, anus and rectum

The severity is variable and 'mild' cases are likely to be missed by ultrasound. However, it is disappointing to note that prenatal diagnosis was only achieved in a single case: a prenatal diagnosis rate of just 14%. This was also remarkable in that the diagnosis was apparently made prior to the spontaneous loss of the pregnancy at 13 weeks gestation. The fetus was found to have other abnormalities including malformation of bladder and imperforate anus and rectum. This, of course, brings us back to the definition of 'date of discovery', (see earlier). The prenatal diagnosis prior to termination was of a large cystic area in the pelvis and abdomen and not Fallot's Tetralogy.

The majority of cases were diagnosed in the first week of life. One case was determined on post-mortem following stillbirth at 30 weeks gestation. Interestingly the diagnosis of this major cardiac abnormality was only made after 1 month in one further case.<sup>6</sup>

#### 4.3.4. Coarctation of the Aorta, (Q251)

A total of seven cases of coarctation of the aorta were seen during 2012-2013. In 6 cases coarctation is the primary diagnosis and in a further case it is listed as a secondary abnormality. All were live births from singleton pregnancies.

Q251	COARCTATION OF AORTA	Prenatal diagnosis
Q251	COARCTATION OF AORTA	Prenatal diagnosis; VSD
Q251	COARCTATION OF AORTA	VSD; ASD
Q251	COARCTATION OF AORTA	VSD
Q251	COARCTATION OF AORTA	VSD; Hypospadias; Congenital pneumonia
Q251	COARCTATION OF AORTA	Congenital aortic insufficiency; Mitral stenosis
D821	DI GEORGE SYNDROME	VSD; Congenital aortic insufficiency; Coarctation of aorta

The prenatal detection rate for this EUROCAT defined Severe Congenital Heart Defect was 29%, (n=2).

<sup>6</sup> The data has been updated since this report was initiated. This case has now been re-classified with a 'date of discovery', when a murmur was first heard, of day 15. The actual diagnosis of Fallot's Tetralogy was made between 1 and 4 weeks

#### 4.3.5. Total Anomalous Pulmonary Venous Drainage, (TAPVD), (Q262)

Total Anomalous Pulmonary Venous Drainage (TAPVD) is difficult to diagnose on prenatal scan unless the drainage is grossly distorted. However, prognosis is generally good.

Q262	TAPVD	Live-birth; Diagnosis at birth
Q262	TAPVD	Live-birth; Prenatal diagnosis; Associated abnormalities

In both cases a male infant was live-born at term. One had a number of associated abnormalities including talipes and malformation of spine.

#### 4.3.6. Ebstein's Anomaly, (Q225)

Ebstein's anomaly is a congenital heart defect in which the septal leaflet of the tricuspid valve is displaced towards the apex of the right ventricle of the heart. The annulus of the valve is still in the normal position. The valve leaflets, however, are to a varying degree, attached to the walls and septum of the right ventricle. There is subsequent 'atrialization' of a portion of the morphologic right ventricle (which is then contiguous with the right atrium). This causes the right atrium to be large and the anatomic right ventricle to be small in size.

There were two cases of Ebstein's Anomaly diagnosed during 2012-2013. In both instances the diagnosis was made shortly after live birth.

Q225	EBSTEIN'S ANOMALY - SEVERE	Persistent Left Superior Vena Cava
Q225	EBSTEIN'S ANOMALY	Pre-excitation Syndrome

#### 4.4. Congenital Malformations of the Respiratory System.

A total of eight respiratory tract abnormalities are classified in the primary diagnostic position. All were live-births at term and prenatal diagnosis of abnormality was achieved in 75% of cases, (n=6). Seven of the abnormalities are considered below as malformations of the broncho-pulmonary foregut. The remaining case was one of chonal atresia which was diagnosed shortly after birth.

##### 4.4.1. Sequestrations, Congenital Cystic Adenomatoid Malformation and Congenital Lobar Emphysema, (Q338, Q3380, P2500).

The respiratory system starts to develop at around 3 week's gestation. Aberrations in the developmental process may give rise to a group of structural malformations collectively referred to as broncho-pulmonary foregut malformations, (BPFM's). The three commonest are Sequestration, Congenital Cystic Adenomatoid Malformation and Congenital Lobar Emphysema.

There were no cases of Pulmonary Sequestration described in the 2012-2013 data.

##### **Congenital Cystic Adenomatoid Malformation, (Q338, Q3380).**

Congenital Cystic Adenomatoid Malformation, (CCAM), is a congenital disorder of the lung similar to bronchopulmonary sequestration and is due to an overgrowth of the terminal bronchioles. Lesions are usually unilateral. It is also known as Congenital Pulmonary Airway Malformation, (CPAM).

There were five cases of Congenital Cystic Adenomatoid Malformation listed.

Q338	CONGENITAL PULMONARY AIRWAY MALF	Prenatal diagnosis; Live-birth
Q3380	CCAM	Prenatal diagnosis; Live-birth
Q3380	CCAM ®	Prenatal diagnosis; Live-birth
Q3380	CCAM (L)	Prenatal diagnosis; Live-birth
Q3380	CCAM ®	Prenatal diagnosis; Live-birth

CCAM is often diagnosed during routine prenatal scanning. It may present as an echogenic mass in the chest of the fetus, a flat or everted diaphragm, and displacement of the heart or absence of any visible lung tissue. CCAM is divided into three types based on gross appearance.

##### **Congenital Lobar Emphysema, (P2500)**

Rather confusingly Congenital Lobar Emphysema is classified under ICD10 as a 'Congenital Infection' rather than a primary abnormality of respiratory tract development. There were two classified cases.

P2500	CONGENITAL LOBAR EMPHYSEMA	Live-birth; Diagnosis after 1 month
P2500	CONGENITAL LOBAR EMPHYSEMA	Prenatal diagnosis; Live-birth

The second case was associated with an unspecified congenital malformation of the spine which may have facilitated early diagnosis.

## 4.5. Face & Neck

### 4.5.1. Cleft Lip & Palate, (Q 352, Q3539, Q3599, Q3690, Q3699, Q378, Q3799)

Cleft lip and palate are common abnormalities seen in approximately 1:600 births. The majority are isolated lesions but they may be part of a chromosomal or other malformation syndrome.

A total of 18 cases are recorded with cleft lip, cleft palate or both.

Fourteen cases of cleft lip were listed overall, (either isolated or associated with cleft palate or other abnormality). Prenatal diagnosis was achieved in 13 cases.

There were six cases of isolated cleft lip. In four cases the abnormality is recorded in the primary position with all live born following prenatal diagnosis. Unilateral cleft lip was also seen in association with one case each of Trisomy 13 and Trisomy 18. These pregnancies were both terminated on the basis of the primary condition.

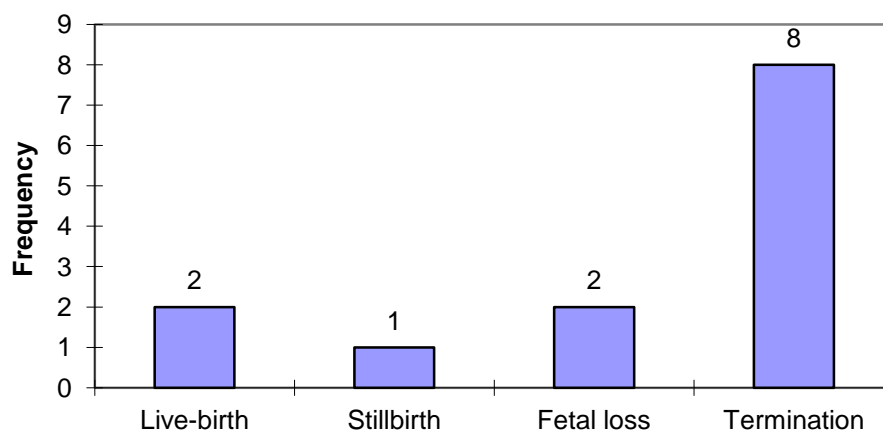
Cleft palate, (with or without cleft lip), was seen in 13 cases. Of these, cleft palate was recorded as a secondary diagnosis in five cases. Where prenatal diagnosis of cleft palate was achieved it was typically in association with another anomaly such as cleft lip or a chromosomal syndrome. None of the 3 cases of isolated cleft palate were diagnosed on antenatal scan they were all diagnosed at birth.

### 4.5.2. Congenital Cavernous Lymphangioma, 'Cystic Hygroma', (D181, D1810).

The presence of a congenital cavernous lymphangioma is recorded for 13 cases. Typically the data only records the presence of a congenital lymphangioma - it does not record location. The presumption is made from the data provided that a 'cystic hygroma' is seen at the neck but lymphangioma may present at other locations such as the limbs. Indeed in the 2012-2013 data set one case of congenital lymphangioma at the knee is recorded in a live-born infant. The diagnosis was made within the first month of life.

Lymphangioma was a primary isolated finding in seven cases and a secondary abnormality in the remaining six. Overall cystic hygroma was associated with chromosomal abnormality in four cases, (30.7%). The majority of cases, (n=11), were identified prenatally.

**Figure 4.6: Outcome of pregnancies associated with cystic hygroma, (n=13)**



Eight cases were terminated following prenatal diagnosis including 4 cases of isolated abnormality. There were 2 live births. There was one stillbirth at 38 weeks, (associated with Trisomy 18), and 2

fetal losses. One of these was a mid-trimester loss at 21 weeks in association with exomphalos. The other was a loss at 16 weeks with isolated cystic hygroma, (Figure 4.6).

#### 4.5.3. Pierre-Robin Sequence, (Q870)

Already mentioned above, there were two cases recorded of Pierre Robin Sequence, (severe micrognathia with a secondary cleft palate).

Q8708	PIERRE ROBIN SEQUENCE	Micrognathia; Unspecified deletion from autosome
Q8708	PIERRE ROBIN SEQUENCE	Micrognathia; Cleft lip and palate

#### 4.5.4. Congenital Cataracts, (Q120)

Approximately one third of congenital cataracts are a component of a more extensive syndrome or disease. However the origin a good 30% are unexplained. Metabolic disease tends to be associated with bilateral cataracts. Typical associations include Alports syndrome, Marfan syndrome, Down syndrome, Myotonic dystrophy, Galactosaemia, Trisomy 13 and congenital infections such as Rubella, Toxoplasmosis, CMV and Herpes Simplex.

There were five cases. All were live-births. In 3 cases the cataracts were bilateral. In the remaining two cases they affected the right eye only. No associated abnormalities were recorded.

Q120	CATARACT - BILAT	Male; Diagnosis 1-4 wks;
Q120	CATARACT ®	Male; Diagnosis 1-12 months;
Q120	CATARACT - BILAT	Male; Diagnosis 1-12 months;
Q120	CATARACT ®	Female; Diagnosis 1-4 wks;
Q120	CATARACT - BILAT	Female; Point of diagnosis unknown;

#### 4.5.5. Other Face & Neck

##### Goldenhar Syndrome, (Q8704)

Also known as Oculo-Auriculo-Vertebral syndrome and presents as incomplete development of the ear, nose, soft palate, lips and mandible. It is believed to be due to anomalous development of the first and second branchial arches late in the first trimester.

One case, in a live-born female infant, is described. The condition was diagnosed at birth.

Q8704	GOLDENHAR SYNDROME ®	Microtia; atresia external auditory canal
-------	----------------------	---

## 4.6. Gastrointestinal Abnormalities

Abnormalities of the abdominal wall such as gastroschisis, exomphalos and congenital diaphragmatic hernia have already been considered, (above). Although most textbooks would consider them as Gastrointestinal Tract Malformations ICD10 codes them, (correctly), as Musculoskeletal Abnormalities.

### 4.6.1. Oesophageal Atresia, (Q391)

There were no cases of oesophageal atresia recorded in the 2012-2013 data.

### 4.6.2. Imperforate Anus, Anal Stenosis & Anorectal Atresia, (Q4228, Q423)

Anorectal atresia affects approximately 1:5000 pregnancies. It is the primary diagnosis in 5 cases all live-births with the diagnosis being made soon after delivery.

Q423	IMPERFORATE ANUS	Male; Congenital malformation of spine
Q423	IMPERFORATE ANUS	Male;
Q423	IMPERFORATE ANUS	Male;
Q423	IMPERFORATE ANUS	Female;
Q423	IMPERFORATE ANUS	Rectovaginal fistula; VSD; Congenital malformation of spine

Anorectal atresia is also described in association with a number of other abnormalities e.g. as a component of VACTERL association. The last case listed above, in a female infant delivered at term, is indeed suggestive of the VACTERL association. Anorectal atresia is recorded as a secondary diagnosis in five further cases.

Q213	TETRALOGY OF FALLOT	Prenatal diagnosis; Fetal loss @ 13wks
Q6410	BLADDER EXSTROPHY (CLOACA)	Female; Live-birth @ term
Q8980	CAUDAL REGRESSION SEQUENCE	Prenatal diagnosis; Stillbirth
Q8980	CAUDAL REGRESSION SEQUENCE	Prenatal diagnosis; Termination
Q910	TRISOMY 18	Prenatal diagnosis; Termination

The overall incidence of anorectal atresia in the NHS GG&C 2012-2013 cohort is 1:1585.

### Ectopic anus

Two cases of ectopic anus are listed, (Q435). Anterior ectopic anus is different from imperforate anus in that the opening is of normal size. Surgery, anoplasty, to relocate the anterior anus is straightforward but affected individuals often have life-long problems with constipation. Whilst anterior displacement is usual in one case the anus is described as being **very** anteriorly placed

Q435	ECTOPIC ANUS – VERY ANTERIOR	Female; Live-birth at term;
------	------------------------------	-----------------------------

In the other case ectopic anus was seen in association with microcephaly.

Q02X	MICROCEPHALY	Male; Live-birth at term
------	--------------	--------------------------

### 4.6.3. Malrotation of Bowel, (Q433)

In ICD10 this is technically 'Congenital Malformations of Intestinal fixation' and includes a variety of conditions of small and large bowel. One case is defined as the primary abnormality with malrotation of the mid-gut such that the duodenal-jejunal flexure and caecum were placed in the left iliac fossa.

Q433	MALROT MIDGUT/ABNY	Female; Live-birth @ 35 wks
------	--------------------	-----------------------------

Malrotation of the colon is also seen as a secondary diagnosis in association with congenital acetabular dysplasia, and deformity of the knee in a female infant delivered at term.

Q660 TEV (L) Female; Live-birth @ term

#### 4.6.4. Other Gastrointestinal Abnormalities

##### **Congenital Biliary Atresia, (Q442)**

Congenital Biliary Atresia is an ICD10 code that can be applied to a collection of abnormalities of the extra hepatic biliary tree that manifest as neonatal jaundice.

Q442 BILIARY ATRESIA Female; Live-birth; Diagnosed after one month  
 Q442 BILIARY ATRESIA Female; Live-birth @ 33 weeks; Prenatal diagnosis

Antenatal diagnosis facilitates the possibility of early definitive surgery.

##### **Hirschsprung's Disease, (Q431)**

Hirschsprung's disease is due to an absence of parasympathetic ganglion cells in the myenteric submucosal plexus of the rectum. This disorder sometimes extends to the colon. It occurs predominantly males with an incidence of 1:5000 births. Hirschsprung's disease typically presents with abdominal distension and failure of passage of meconium within the first 48hrs. Recognized associations include multiple endocrine neoplasia, Wardenburg's syndrome & Down syndrome.

Two cases were defined as primary disorders.

Q431 HIRSCHSPRUNG'S DISEASE Live-birth; Term; Male  
 Q431 HIRSCHSPRUNG'S DISEASE Live-birth; Term; Female

One of the above cases of Hirschsprung's disease in a male infant was associated with an 'unspecified' deletion from an autosome, (Q938),<sup>7</sup> facial abnormalities, and a further 'unspecified' anomaly of the peripheral vascular system.

##### **Foregut Duplication Cysts, (Q434)**

Foregut duplication cysts are rare congenital anomalies of enteric origin. In majority of the patients, the diagnosis is made in infancy.

Q434 DUPLICATION CYST OF SMALL BOWEL Live-birth; Prenatal Diagnosis  
 Q434 DUPLICATION CYST - ILEAL Live-birth; Diagnosed 1<sup>st</sup> week of life  
 Q434 FOREGUT DUPLICATION CYST Live-birth; Prenatal Diagnosis

##### **Small Bowel Atresia, (Q410, Q419)**

Duodenal atresia is seen in approximately 1:10,000 pregnancies. The classic 'double bubble' is due to dilatation of both stomach and the first part of the duodenum proximal to the obstruction. In 30% of cases it is associated with other disorder and in particular there is a well recognized association with Trisomy 21, (Down syndrome). One case is described in the data as a secondary diagnosis with Trisomy 21.

Q909 TRISOMY 21 Prenatal diagnosis; Live-birth @ 35 weeks; Duodenal Atresia; AVSD

<sup>7</sup> Q938 can be a rather vague ICD10 coding. It is also used to denote a Chromosome 1p36 deletion.

## 4.7. Renal & Urinary System

Renal tract abnormalities are seen in about 10% of live born babies. They may be isolated or components of a recognizable syndromes. They are simply divided into malformations of the kidneys (i.e. renal agenesis & renal dysplasia) and abnormalities of the collecting system (i.e. posterior urethral valves). The ICD10 classification divides the abnormalities into renal agenesis and reduction defects, cystic kidney disease and congenital obstruction defects.

### 4.7.1. Renal Agenesis and Other Reduction Defects, (Q600, Q601, Q602)

These are typically the result of failure of the ureteric bud to develop so that the ureter and kidney are absent. If unilateral the child will live a full and healthy life provided the other kidney is normal. Bilateral agenesis is lethal and is usually diagnosed when profound oligohydramnios is seen on antenatal scan.

#### Bilateral Renal Agenesis, (Q602)

There were two cases recorded of bilateral renal agenesis; both cases as the primary diagnosis.

Q602	RENAL AGENESIS	Prenatal diagnosis; Termination
Q602	RENAL AGENESIS	Prenatal diagnosis; Fetal loss @ 24 weeks

#### Unilateral Renal Agenesis, (Q600)

A total of nine cases of unilateral renal agenesis were listed. In seven it is given as the primary diagnosis. A prenatal diagnosis was made in all cases. The majority progressed to live-birth at term. One case, associated with other abnormalities, was terminated at 22 weeks gestation.

Q600	ABSENT KIDNEY (L)	Prenatal diagnosis; Live-birth
Q600	ABSENT KIDNEY (L)	Prenatal diagnosis; Live-birth
Q600	ABSENT KIDNEY ®	Prenatal diagnosis; Live-birth
Q600	RENAL AGENESIS ®	Prenatal diagnosis; Live-birth
Q600	ABSENT KIDNEY ®	Prenatal diagnosis; Live-birth
Q600	ABSENT KIDNEY (L)	Prenatal diagnosis; Live-birth
Q600	ABSENT KIDNEY	Dysplastic kidney; Congenital malformation of spine

In a further two cases the abnormality is recorded as an associated feature.

Q8980	CAUDAL REGRESSION SEQUENCE	Prenatal diagnosis; Stillbirth @ 25 weeks
Q2542	AORTIC VALVE OVERRIDES VSD	Prenatal diagnosis; Stillbirth @ 37 weeks

### 4.7.2. Cystic Kidney Disease (Q611, Q614, Q6141)

Dysplastic kidneys contain abnormally differentiated parenchyma. They are commonly associated with obstruction and other abnormalities of the urinary tract. Nine disorders are listed in the primary position. Prenatal diagnosis was achieved for all listed cases.

Q611	POLYCYSTIC KIDNEY DISEASE	Female; Stillbirth @28 wks.
Q614	RENAL DYSPLASIA ®	
Q614	DYSPLASTIC KIDNEY (L)	
Q614	SMALL DYSPLASTIC KIDNEY ®	
Q614	RENAL DYSPLASIA	Multiple abnormalities
Q614	DYSPLASTIC ® KIDNEY	Agenesis of ureter
Q6140	MULTICYSTIC RENAL DYSPLASIA ®	
Q6140	MULTICYSTIC DYSPLASTIC KIDNEY (L)	Patent ductus arteriosus;
Q6141	MULTICYSTIC DYSPLASTIC KIDNEY	



A further two cases are recorded as associated findings.

Q630	DUPLEX SYSTEM ®	Live-birth; Polycystic kidney
Q8726	VATER ASSOCIATION	Termination; Fibrocystic kidney

The majority of cases were live born. However there was one termination of pregnancy at 21 weeks following the prenatal diagnosis of VATER Association. Furthermore a female infant was stillborn at 28 weeks gestation following the prenatal diagnosis of bilateral severe infantile polycystic kidney disease.

#### 4.7.3. Congenital Obstructive Defects of Renal Pelvis & Malformation of Ureter, (Q62)

This ICD10 category includes a variety of abnormalities of the renal and urinary system including, congenital hydronephrosis, atresia and stenosis of the ureter, agenesis of ureter and congenital PUJ obstruction.

##### **Congenital PUJ Obstruction, (Q623)**

This abnormality is seen in two cases, once as a primary abnormality and then as a secondary abnormality in association with a duplex collecting system. In both case the lesion was on the left side in a female infant live-born at term. Where Congenital PUJ Obstruction appears as the primary abnormality prenatal diagnosis was achieved. The case of PUJ obstruction in association with a duplex collecting system was diagnosed after one month of life.

#### 4.7.4. Other Congenital Malformations of the Kidney, (Q63)

##### **Duplex Kidney and Collecting System, (Q630)**

Q630	DUPLEX KIDNEY (L)	Single Umbilical Artery
Q630	DUPLEX KIDNEY ®	
Q630	DUPLEX KIDNEY (L)	
Q630	DUPLEX (L) SYSTEM	Congenital PUJ Obstruction
Q630	DUPLEX KIDNEY (L)	
Q630	DUPLEX SYSTEM ®	Polycystic kidney
Q630	DUPLEX KIDNEY ®	Accessory toe
Q630	DUPLEX KIDNEY ®	Congenital non-neoplastic naevus

##### **Abnormally Sited Kidney, (Q631, Q632, Q6320, Q6322)**

Abnormal renal situs is recorded as a primary abnormality on two occasions.

Q6320	PELVIC KIDNEY ®	Congenital malformation spinal cord
Q6322	CROSSED FUSED ECTOPIA ®	Female; Prenatal diagnosis; Live-birth

It is also described as a secondary abnormality in a further four cases.

Q6580	DDH (L)	Horseshoe Kidney
Q910	TRISOMY 18	Ectopic Kidney
Q963	MOSAIC TURNER'S	Horseshoe Kidney
Q0511	THORACIC MYELOMENINGOCELE	Crossed Fused Ectopia; Male; Live-birth

When a kidney is located on the side opposite from where its ureter inserts into the bladder, it is defined as crossed renal ectopia. If that kidney is also fused with the opposite kidney then it is known as crossed fused renal ectopia. Ninety percent of crossed ectopic kidneys are fused to their contra-lateral mate. It is most commonly found in boys and the left moiety is crossed to the right in the majority of cases. Associated urological problems are commonly present.

#### 4.7.5. Other Congenital Anomalities, (Q64)

##### Bladder Exstrophy

The exstrophy epispadis complex is a spectrum of disorder ranging in severity from epispadis through bladder exstrophy to cloacal exstrophy. The described case in a female infant seems to have been at the more severe end of the spectrum.

Q6410 BLADDER EXSTROPHY (CLOACA) Exomphalos; Imperforate anus;

##### Posterior Urethral Valves

Posterior urethral valves are the most common cause of lower urinary tract obstruction in the male neonate. The disorder is of variable severity. The condition arises around the 4<sup>th</sup> week of gestation as the Wolffian ducts fuse with the developing cloaca.

Q642 POSTERIOR URETHRAL VALVES Male; Live-birth; Diagnosis 1-12 months  
 Q642 POSTERIOR URETHRAL VALVES Male; Live-birth; Prenatal diagnosis

#### 4.7.6. Hypospadias, (Q540, Q541, Q542, Q549)

Hypospadias occurs in 1:350 male children. It is the commonest abnormality of the male genitalia and the third commonest abnormality listed in this 2012-2013 series. The urethra opens on the ventral aspect of the penis at a point proximal to the normal site. The frenulum is almost always affected being imperfectly formed and this deformity may be more obvious than the hypospadias itself.

There were twenty-one cases where hypospadias was recorded as the primary diagnosis. It is also recorded as a secondary diagnosis in five further cases.

Q251 COARCTATION OF AORTA  
 Q564 AMBIGUOUS GENITALIA Hypospadias; Hypoplasia penis  
 Q564 AMBIGUOUS GENITALIA Hypospadias  
 Q660 CTEV (L)  
 Q700 ACROSYNDACTYLY- BILAT

The overall incidence of this abnormality is 1:720 maternities. In all cases the gender is given as male. All were diagnosed soon after birth with the exception of one previously noted case.

## 4.8. Musculo-Skeletal Abnormalities

This is the largest grouping of congenital abnormalities.

### 4.8.1. Congenital deformity of the hip, (Q651, Q6580, Q6581)

Dislocated hips are associated with joint laxity and acetabular dysplasia. Postural features often play a role in their causation. They are commonest in female infants, term deliveries, breech presentation and the left hip. Diagnosis is made at birth by specifically testing the hips.

A total of 21 cases of Congenital Dislocation of the Hip are listed. In seventeen cases CDH is the main diagnosis and in the remaining four is noted as a secondary abnormality.

Q660	TEV (L)	CDH; Atresia of bowel; Malrotation of colon; Deformity of knee
Q743	ARTHROGRYPOSIS	Talipes; Bilateral DDH; Micrognathia
Q743	ARTHROGRYPOSIS	Talipes calcaneo-valgus; CDH
Q809	ICTHYOSIS	Congenital hip deformity unspecified

The majority of cases were diagnosed in the first week of life, (n=14). Six cases were not diagnosed until after one month. The case of talipes equino-varus with multiple abnormalities was diagnosed on prenatal scan.

All twenty-one cases observed were in female infants.

### 4.8.2. Achondroplasia, (Q774)

Achondroplasia is a non-lethal short limb dysplasia which may not be apparent until the time of birth. Two cases of achondroplasia were diagnosed after live birth. A sporadic mutation is the cause in 80% of cases but achondroplasia may be inherited as an autosomal dominant disorder. The causative mutation is in Fibroblast Growth Factor Receptor 3.

Q774	ACHONDROPLASIA	Female;
Q774	ACHONDROPLASIA	Female; Congenital varicella syndrome

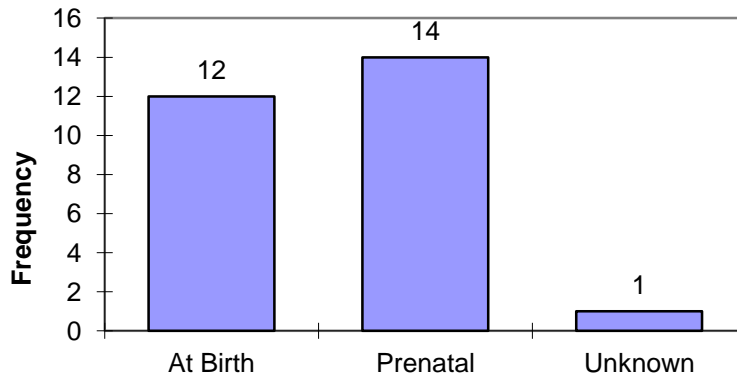
The association of one case with congenital varicella syndrome, (P358), is curious and suggests some diagnostic uncertainty: this case was not 'discovered' until after 1 week.

### 4.8.3. Talipes Equino Varus, (Q660)

Minor degrees of talipes are common at birth, resulting from mechanical pressure *in utero*. The commonest deviation is one in which there is plantar flexion, (equinus), and foot adduction, (varus), at the mid-tarsal joint. The birth incidence is commonly stated as 1:1000. For the year 2012-2013 talipes equino varus (TEV) is recorded in the primary diagnostic position on twenty-seven occasions with a Male:Female ratio of 3:1. The majority of cases, (51.8%) were diagnosed on antenatal scan, (Figure 4.7).

Talipes equino varus was the most common abnormality detected during the 2012-2013 review. The overall incidence of TEV during 2012-2013 was 1:466 maternities.

**Figure 4.7: Point of Diagnosis of Talipes Equino Varus as a primary abnormality, (n=27)**



Talipes equino varus is also coded as a secondary diagnosis in a further eight cases. Once again the male gender predominates.

Q262	TAPVD	
Q743	ARTHROGRYPOSIS	
Q743	ARTHROGRYPOSIS	Micrognathia; Bilateral DDH;
Q7980	AMNIOTIC RUPTURE SEQUENCE	Termination
Q8480	APLASIA CUTIS	
Q8980	CAUDAL REGRESSION SEQUENCE	Termination
Q913	TRISOMY 18	Termination
Q913	TRISOMY 18	Termination

**4.8.4. Limb Reduction Defects, (Q71, Q72).**

This is a wide spectrum of disorder most commonly involving shortened or absent bones. Six cases are listed as primary limb reduction abnormalities.

Q713	ABSENT FINGERS ®	
Q7131	RUDIMENTARY THUMB - BILAT	Absent radius
Q714	RADIAL CLUB HAND BILAT	
Q714	ABSENT RADIUS (L)	Congenital shortening upper limb
Q715	SHORTENED ULNA (L)	Absent radius
Q724	FIBULAR HEMIMELIA - BILAT	Reduction defect of tibia; absence of foot

In a further three cases one or more limb reduction defects are listed as secondary abnormalities.

Q7980	AMNIOTIC RUPTURE SEQUENCE	Congenital absence of hand and foot;
Q8726	VACTERL ASSOCIATION	Clubhand; Congenital absence of hand
Q019	ENCEPHALOCELE	Shortening of upper and lower limbs

**4.8.5. Craniosynostosis (Q750)**

Craniosynostosis is due to the premature closure of one or more of the skull sutures. It affects about 1:2500 children. Craniosynostosis causes distortion of the shape of the skull owing both to failure of bone growth at the prematurely closed suture site and to compensatory overgrowth at the sutures that remain open. The different types of craniosynostosis are classified by which sutures have closed prematurely. Four primary cases are described with a further case associated with Horner’s Syndrome, (G902).

#### 4.8.6. Other Musculo-Skeletal Abnormalities

##### Arthrogryposis, (Q743)

Arthrogryposis is not really a diagnosis but a description that refers to a number of pathological processes resulting in limb immobilization and multiple congenital joint contractures. It is therefore a rather heterogenous grouping of conditions both syndromic, (e.g. Larsen syndrome, Freeman-Shelden syndrome and Multiple Pterigium syndrome) and non-syndromic. Three cases were described, all in the primary diagnostic position.

Q743	ARTHROGRYPOSIS	Live-birth; Prenatal diagnosis; Male
Q743	ARTHROGRYPOSIS	Live-birth; Diagnosed at birth; Female
Q743	ARTHROGRYPOSIS	Live-birth; Diagnosed at birth; Female

Associated features included talipes and congenital deformity of the hip, (see above).

##### Larsen Syndrome, (Q7484)

This rare disorder is caused by a genetic defect in the gene encoding filamin B, a cytoplasmic protein that is important in regulating the structure and activity of the cytoskeleton. The gene that influences the emergence of Larsen syndrome is found in chromosome region, 3p21.1-14.1, a region containing the Human type VII collagen gene. Patients suffering from Larsen syndrome normally present with a variety of symptoms including: congenital anterior dislocation of the knees, dislocation of the hips and elbows, flattened facial appearance, prominent foreheads, and depressed nasal bridges. Larsen syndrome is also associated with a variety of cardiovascular anomalies and orthopaedic abnormalities.

Q7484	LARSEN'S SYNDROME	Prenatal diagnosis; Live-birth; Knee abnormality
-------	-------------------	--

##### Osteogenesis Imperfecta, (Q780)

These 'brittle-bone' disorders are due to an abnormality of collagen. Prenatal diagnosis was achieved for all cases.

Q780	OSTEOGENESIS IMPERFECTA TYPE 2	Termination; Female
Q7800	OSTEOGENESIS IMPERFECTA	Live-birth; Female
Q7800	OSTEOGENESIS IMPERFECTA	Live-birth; Female

##### Congenital Malformations of the spine not associated with scoliosis, (Q764)

This is a broad classification under ICD10 and includes fusion of the spine, absence of vertebrae, hemi-vertebrae, malformation of the lumbo-sacral joint and supernumerary vertebrae.

Q764	OTHER CONGENITAL MALFORMATION OF SPINE	Male; Live-birth @ term
------	--	-------------------------

Congenital malformation of the spine was also an associated feature in eight further cases.

P2500	CONGENITAL LOBAR EMPHYSEMA	
Q258	MALFORMATION OF GREAT ARTERIES	
Q423	IMPERFORATE ANUS	Rectovaginal fistula; VSD;
Q434	FOREGUT DUPLICATION CYST	
Q600	ABSENT KIDNEY	Dysplastic kidney;
Q795	ABDOMINAL WALL DISRUPTION - SEVERE	
Q795	ANTERIOR ABDOMINAL WALL DEFECT	
Q927	TRIPLOIDY	ASD; Hypoplasia uterus and cervix;

## 4.9. Abdominal Wall Defect

ICD10 Codes Q790-Q799 are 'Congenital malformations of the musculoskeletal system, NEC' and includes Congenital Diaphragmatic Hernia, Exomphalos, Gastroschisis and Amniotic Rupture Sequence - collectively considered here as 'Abdominal Wall Defects'.

### 4.9.1. Congenital Diaphragmatic Hernia, (Q790)

This is a defect of the hemi-diaphragm, usually on the left side. All cases are associated with an abnormality of gut rotation.

In the 2012-2013 there were no cases listed of Congenital Diaphragmatic Hernia. However a case is described of Eventration of the Left Diaphragm in a female infant delivered at term.

Q7910      EVENTRATION DIAPHRAGM (L)      Prenatal diagnosis; No associated abnormalities

### 4.9.2. Gastroschisis, (Q793)

Seven cases of gastroschisis were diagnosed on antenatal scan. There were no associated abnormalities; gastroschisis was an isolated lesion in all cases. Overall incidence for this lesion was 1:2265 maternities. They were all live-births with a mean gestation at delivery of 34.8 weeks. Prenatal diagnosis was achieved for all cases. Gastroschisis is also associated with a young maternal age. Mother's under the age of 20 years are twelve times more likely to have an infant with gastroschisis. Mean maternal age was 24.7 years. Two mothers were less than 20 years of age.

### 4.9.3. Exomphalos, (Q792)

Exomphalos is the result of the physiological herniation of the gut into the umbilical cord and the failure of the intestinal loops to return to the fetal abdomen. Typically membrane covered, it is often seen with associated malformations.

A total of seven cases of exomphalos are coded in the data, an incidence of 1:2265 maternities. It is given as the primary diagnosis in four cases.

Q792	EXOMPHALOS	Live-birth
Q792	EXOMPHALOS - SMALL	Live-birth
Q792	EXOMPHALOS	Late fetal loss @ 21 weeks;
Q792	EXOMPHALOS	Termination @ 21 weeks

Exomphalos was an associated abnormality in three cases.

Q6410	BLADDER EXTROPHY (CLOACA)	Exomphalos; Imperforate anus; Ambiguous genitalia
Q913	TRISOMY 18	Exomphalos; Talipes
Q914	TRISOMY 13	Exomphalos; Holoprosencephaly; Proboscus

Prenatal diagnosis was achieved in six cases of the seven cases. In the remaining case, (fetal loss at 21 weeks), the point of diagnosis is recorded as unknown. For comparison with gastroschisis mean maternal age was 29.8 years.

### 4.9.4. Other Abdominal Wall Defect, (Q795)

Three further cases of anterior abdominal wall disruption are coded in the data. All were associated with congenital malformations of the spine. This ICD10 code specifically excludes umbilical hernia.

Q795	ABDOMINAL WALL DISRUPTION	Live-birth; Malformation of spine
Q795	ANTERIOR ABDOMINAL WALL DEFECT	Termination; Malformation of spine
Q795	ANTERIOR ABDOMINAL WALL DEFECT	Termination; Fusion of hemivertebrae

#### 4.9.5. Amniotic Band Sequence, (Q7980)

The commonly accepted view is that amniotic band sequence is a consequence of amniotic rupture without injury to the chorion. Fibrous bands of the ruptured amnion 'float' and can encircle and trap fetal parts. Later as the fetus grows but the bands do not, the bands become constricting. In some cases a complete amputation of a digit or limb may occur. Amniotic bands can also attach to the face or neck causing deformities such as cleft lip and palate.

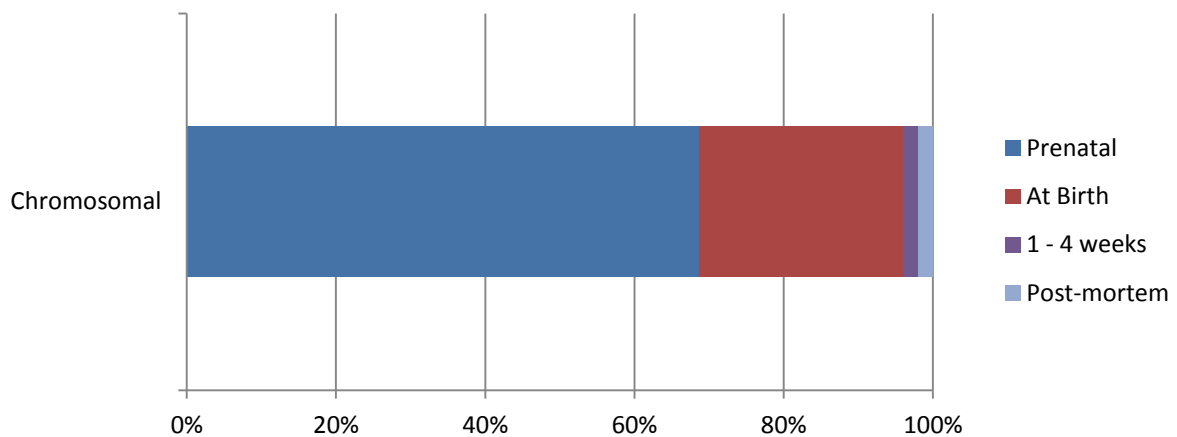
Three cases of Amniotic Band Sequence are listed. One, a termination of pregnancy at 22 weeks gestation following prenatal diagnosis, had a number of associated abnormalities including cleft lip and palate, congenital absence of hand, talipes equino-varus and congenital absence of a foot.

Q7980	AMNIOTIC BAND SEQUENCE	Fetal loss at 20 weeks; Post-mortem diagnosis
Q7980	AMNIOTIC RUPTURE SEQUENCE	Termination; Multiple abnormalities
Q7980	AMNIOTIC BANDS	Termination

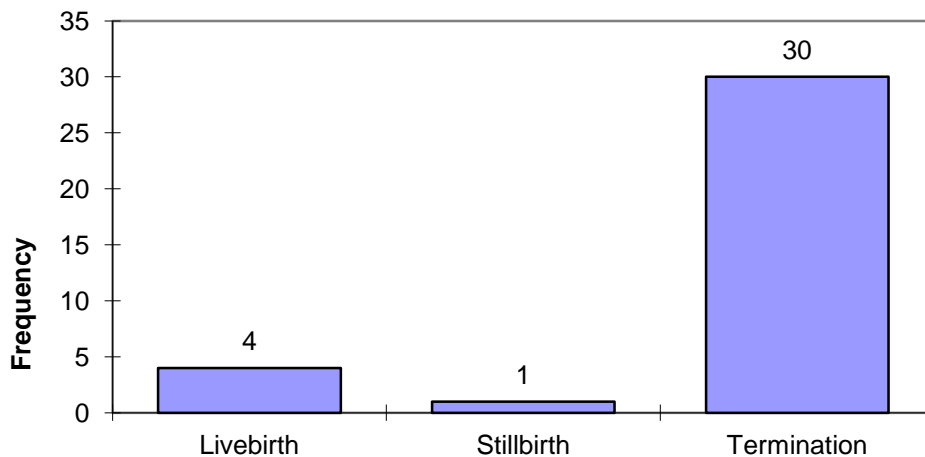
### 4.10. Chromosomal Abnormality

A chromosomal abnormality is recorded in the primary or secondary position for 55 cases, (15%). They account for 10.7% of all abnormalities detected in the 2012-2013 cohort. The majority, (n=51), are recorded as the primary diagnosis.

**Figure 4.7: Point of Diagnosis of Primary Chromosomal Abnormality**



**Figure 4.8: Outcome of Pregnancy following Prenatal Diagnosis of Chromosomal Abnormality, (n=35)**



There were 4 cases where a defined chromosomal abnormality is not recorded as the primary diagnosis.

Q042	HOLOPROSENCEPHALY	Triploidy; Prenatal diagnosis; Termination
Q2542	AORTIC VALVE OVERRIDES VSD	Chromosomal unspec.; Prenatal diagnosis; Stillbirth
Q431	HIRSCHSPRUNG'S DISEASE	Livebirth @ 40 wks; Deletion from autosome
Q8708	PIERRE ROBIN SEQUENCE	Livebirth; Late diagnosis; Deletion from autosome



One stillbirth is classified as having an ‘unspecified’ chromosomal abnormality, (Q998). A number of congenital abnormalities had been diagnosed antenatally including aortic atresia, unilateral renal agenesis and VSD. The primary abnormality was, however, recorded as ‘Other Congenital malformations of the Aorta’, specifically ‘Aortic Valve over-rides VSD’.

A partial deletion from an unspecified autosome, (Q938), is noted in association with Hirschsprung’s disease and congenital abnormalities of both the face and peripheral vascular system. A similar deletion, (Q939), is also seen in association with a case of Pierre Robin Sequence.

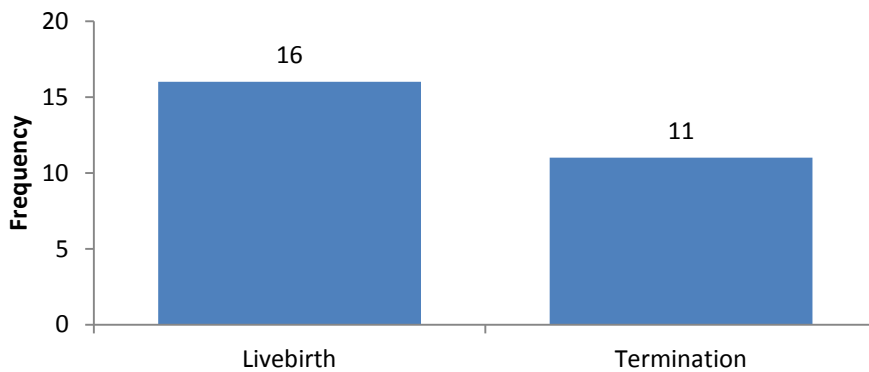
Di George Syndrome (22q11.2 deletion) is classified as a primary blood disorder under ICD10. It is not considered a primary chromosomal abnormality.

D281	DI GEORGE SYNDROME	Female; Livebirth @ 41wks;
D281	DI GEORGE SYNDROME	Prenatal diagnosis; Termination @ 16wks

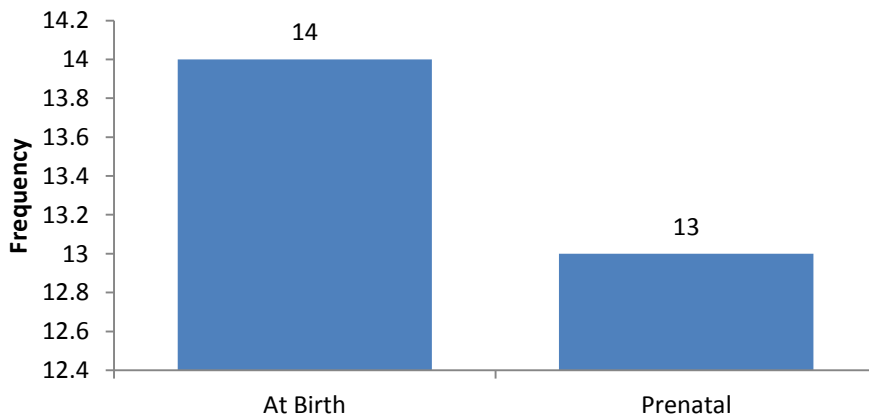
**4.10.1. Trisomy 21 (Down syndrome), (Q900, Q909)**

A total of 27 cases were associated with Trisomy 21, (incidence of 1:587 maternities). Trisomy 21 was always recorded as a primary abnormality. Fifty-nine percent of cases, (n=16), were live born. The remaining eleven cases were terminated following prenatal diagnosis, (Figure 4.9).

**Figure 4.9: Outcome of pregnancies associated with Trisomy 21, (n=27)**



**Figure 4.10: Point of diagnosis of Trisomy 21, (n=27)**



The data does not provide any information on whether or not women were offered antenatal screening for Down syndrome, if screening was performed but returned as low risk, or if a high risk on screening was not followed up by a diagnostic test. This more detailed information should be available through the GG&C PNBS programme and clearly this is an area for further review.<sup>8</sup>

#### 4.10.2. Trisomy 18, (Q910, Q913)

There were 12 cases of Trisomy 18 (Edward's syndrome) listed in the data. All were diagnosed antenatally.

Q910	TRISOMY 18	Prenatal diagnosis; Livebirth; TOF; VSD; Coarctation of aorta
Q910	TRISOMY 18	Cystic hygroma; Prenatal diagnosis; Stillbirth
Q910	TRISOMY 18	Prenatal diagnosis; Termination; Multiple abnormalities
Q910	TRISOMY 18	Prenatal diagnosis; Termination; Unilateral Cleft Lip
Q910	TRISOMY 18	Prenatal diagnosis; Termination; Multiple abnormalities
Q913	EDWARDS SYNDROME	Prenatal diagnosis; Termination;
Q913	EDWARDS SYNDROME	Prenatal diagnosis; Termination;
Q913	EDWARDS SYNDROME	Prenatal diagnosis; Termination;
Q913	EDWARDS SYNDROME	Prenatal diagnosis; Termination;
Q913	TRISOMY 18	Prenatal diagnosis; Termination;
Q913	TRISOMY 18	Prenatal diagnosis; Termination; Talipes
Q913	TRISOMY 18	Prenatal diagnosis; Termination; Exomphalos; Talipes

Cardiac abnormalities are commonly associated with Trisomy 18 yet in this series only one case, (8.3%), has any mention of cardiac defects. Of course cardiac abnormalities may have been seen in the two cases classified with multiple but unspecified abnormalities.<sup>9</sup>

#### 4.10.3. Trisomy 13, (Q914, Q917)

There were 4 diagnosed cases of Trisomy 13 (Patau's syndrome). All were diagnosed antenatally and terminated. Holoprosencephaly was an associated feature in one case.

Q914	TRISOMY 13	
Q914	TRISOMY 13	Cleft Lip; VSD; Malposition of heart
Q914	TRISOMY 13	Holoprosencephaly; Exomphalos; Proboscus
Q917	PATAU'S SYNDROME	

#### 4.10.4. Turner syndrome, (Q960, Q963, Q967)

Turner syndrome is an aneuploidy, and is also known as 'Monosomy X', (45XO). Fifteen percent of cases demonstrate some mosaicism. Sometimes a lymphangioma, (cystic hygroma), prompts diagnostic investigation. Two cases were diagnosed prenatally.

Q960	TURNER'S SYNDROME	Cystic hygroma; Termination @ 13 wks
Q963	MOSAIC TURNER'S	Livebirth @ 39 wks; Horseshoe kidney

#### 4.10.5. Triploidy, (Q927)

Triploidy, (69 XXY, XXX or XYY), in which the fetus gains a complete extra set of chromosomes derived from the father, is thought to occur in up to 2% of conceptions. It is recorded as a primary diagnosis in three cases.

<sup>8</sup> Indeed some additional information is already available and could be included in future reports, (see earlier).

<sup>9</sup> Unfortunately this is due to a lack of available follow-up information and correspondence regarding antenatal screening, ultrasound diagnosis and post-mortem findings. Hopefully the use of systems such as PNBS will improve both data hygiene and integrity.

Q927	TRIPLOIDY	Prenatal diagnosis; Termination;
Q927	TRIPLOIDY	Prenatal diagnosis; Termination;
Q927	TRIPLOIDY	Prenatal diagnosis; Termination; ASD; Uterine hypoplasia

A further case of Triploidy is recorded in association with Holoprosencephaly, (see earlier).

#### 4.10.6. Klinefelter syndrome, (Q980)

Klinefelter syndrome, (47, XXY), affects 1:1000 males and is typically diagnosed in early adulthood during investigations of infertility. Two cases of Klinefelter syndrome were diagnosed during 2011-2012.

Q980	KLINFELTER'S	Stillbirth; Diagnosis at post-mortem
Q980	KLINFELTER'S SYNDROME	Prenatal diagnosis; Termination at 12wks

#### 4.10.7. Other Genetic

There were other conditions with a chromosomal origin that are rather haphazardly classified as 'Other Congenital' Abnormalities under ICD10. Di George syndrome, classified as a primary blood disorder under ICD10, has already been mentioned. They are considered here in order to avoid missing them out of the review.

#### Chromosome 1p36 Deletion, (Q938)<sup>10</sup>

Deletions of the distal short arm of chromosome1 (1p36) represent a fairly common syndrome characterized by moderate to severe psychomotor retardation, seizures, growth delay and dysmorphic features. In all cases the anterior fontanelle is large. Pointed chin, flat nasal bridge and clinodactyly are seen in two-thirds or more of cases. Ear asymmetry and hearing deficits are also common occurring in more than half of affected children.

Q938	CHROMOSOME 1p36 DELETION	Female; Live-birth; Diagnosed between 1-4 weeks
------	--------------------------	---

#### Williams syndrome, (Q8784)<sup>11</sup>

This is a sporadic congenital syndrome that is a consequence of a micro-deletion of chromosome 7, (7q11, 23) at the elastin gene focus. Affected individuals have a typical 'clown-like' facies and global developmental delay with hyperacusis. They often have good verbal and social skills but are unable to live independently exhibiting high anxiety and fearfulness. William's syndrome can be associated with supravalvular aortic stenosis and peripheral pulmonary artery stenosis however no associated features were seen in the one case described.

Q8784	WILLIAM'S SYNDROME	Male; Live-birth; Diagnosed after 1 month
-------	--------------------	---

#### Prader-Willi syndrome, (Q8715)<sup>12</sup>

Prader-Willi syndrome is the result of the loss of expression of maternally imprinted genes on Chromosome 15 of paternal origin. In most cases both copies of chromosome 15 are of maternal origin, (maternal disomy), with a deletion of 15q11-q13.

Q8715	PRADER-WILLI SYNDROME	Female; Live-birth at term; Diagnosed after 1 week
-------	-----------------------	--

<sup>10</sup> Another vague ICD10 coding 'Other deletions from the autosomes'

<sup>11</sup> The case of Stickler Syndrome described earlier shares the same ICD10 coding of Q878 'Other specified congenital malformation syndromes, not elsewhere classified'.

<sup>12</sup> Again ICD10 coding simply classifies Prader-Willi syndrome as a 'Congenital malformation syndrome predominantly associated with short stature'.

## Appendix 1

### NHS Greater Glasgow & Clyde Maternities 1<sup>st</sup> April 2012 – 31<sup>st</sup> March 2013

	Appointed Referrals Non-NHSGGC Residents	Appointed Referrals NHSGGC Residents	Total Appointed Referrals	Bookers Non-NHSGGC Residents	Bookers NHSGGC Residents	Total Bookers
Princess Royal Maternity	1248	5444	6692	1067	4834	5901
Royal Alexandra Hospital	384	3414	3798	347	3207	3554
Southern General Hospital	422	6618	7040	318	5889	6207
Not recorded	53	146	199	51	144	195
<b>Total</b>	<b>2107</b>	<b>15622</b>	<b>17729</b>	<b>1783</b>	<b>14074</b>	<b>15857</b>

### Births NHS GG&C 1<sup>st</sup> April 2012 to 31<sup>st</sup> March 2013

	Clyde	Glasgow	Total
Live birth	3463	10608	14071
Stillbirth	9	29	38
<b>Total</b>	<b>3472</b>	<b>10637</b>	<b>14109</b>

## Appendix 2

### Case Prevalence Comparison, (per 10,000 births) ‡.

Abnormality	Prevalence in Primary Position	Prevalence in any Position	EUROCAT Prevalence Data*
Amniotic Band Sequence, (Q7980)	2.12	2.12	0.51
CCAM,(Q338)	3.54	3.54	0.95
Bilateral Renal Agenesis, (Q602)	1.42	1.42	1.18
Congenital cataract, (Q120)	3.54	3.54	1.23
Hirschsprung's Disease, (Q431)	1.42	1.42	1.24
Turner Syndrome, (Q914-917)	1.42	1.42	2.24
Craniosynostosis, (Q750)	2.83	3.54	2.39
Hypoplastic Left Heart, (Q234)	3.54	3.54	2.66
Congenital Diaphragmatic Hernia, (Q790)	0.0	0.0	2.76
Gastroschisis, (Q793)	4.96	4.96	2.85
Exomphalos, (Q792)	2.83	4.96	3.00
Fallot's Tetralogy, (Q213)	4.96	4.96	3.45
Transposition of Great Arteries, (Q203)	1.42	1.42	3.52
Coarctation of the aorta, (Q251)	4.24	4.96	3.85
Atrioventricular septal defect, (Q212)	0.0	2.12	4.09
Edwards Syndrome, (Q910-913)	8.5	8.5	5.13
Hydrocephalus, (Q030-039)	2.12	2.12	5.77
Hip dislocation and/or dysplasia, (Q651)	12.05	14.88	8.07
Cleft Lip/Palate, (Q352-3799)	7.78	12.76	8.77
NTD's, (Q000,Q010-019, Q051-059)	7.08	7.80	9.66
Hypospadias, (Q549)	14.88	18.42	18.01
Down Syndrome, (Q900-909)	19.14	19.14	22.1

‡Denominators: The congenital anomaly surveillance tool that has been used to compile the data within this report is restricted to mothers' resident within the geographically defined area of NHS GG&C at the time of birth. In order to allow comparison with the EUROCAT prevalence data the appropriate denominator for the prevalence data is therefore the total live births and stillbirths for that area during 2012-2013 which is 14,109, (14,071 live births and 38 stillbirths).

\*Source for comparison data: EUROCAT Website Database. The EUROCAT prevalence data quoted is for 2007-2011.

## Appendix 3

### Prenatal Detection Rates: Comparison with 'established' data

Abnormality	Observed Prenatal Detection Rate	Expected Detection Rate*
Anencephaly	100%	98% (96.7%)
Open Spina Bifida	100%	90% (82.9%)
Diaphragmatic Hernia (Q790)	No cases	60% (58.0%)
Cleft Lip ◊	72.2%	75% (50.7%)
Gastroschisis	100%	98% (91.6%)
Exomphalos	86%	80% (83%)
Serious Cardiac Abnormalities (EUROCAT defined)	40%	50%
Transposition of Great Vessels (Q203)	0%	(41.4%)
Atrioventricular septal defect (Q212)	66%	
Fallot's Tetralogy (Q213)	14%	
Ebstein's Anomaly (Q225)	0%	
Hypoplastic Left Heart (Q234, Q248)	80%	(71.9%)
Hypoplastic Right Heart (Q226)	100%	
Coarctation of Aorta (Q251)	29%	
Bilateral Renal Agenesis	100%	84% (88.1%)
Talipes Equino-varus	51.8%	(39.8%)
Trisomy 21	48.1%	95% (63.8%)
Trisomy 18	100%	95% (90.9%)
Trisomy 13	100%	95% (90.9%)

◊ Figures vary depending on whether or not looking at cleft lip alone, in combination with palate defect, or as part of a complex or syndrome. Figure given is for any cleft lip, (primary or secondary abnormality, isolated or in association with cleft palate).

\*Ward P & Soothill P. Fetal Anomaly ultrasound scanning: the development of a national programme for England. TOG 2011; 13: 211-217. Figures in brackets relate to EUROCAT observed Prenatal Detection Rates.