

NHS Greater Glasgow & Clyde

CONGENITAL ANOMALIES SURVEILLANCE

2013-2014

**REVIEW OF DATA RELATING TO CONGENITAL
ANOMALIES DETECTED IN NHS GG&C
BETWEEN
1ST APRIL 2013 AND 31ST MARCH 2014**

Dr. James Robins

Source data provided by Hilary Jordan of Information Services

Final

18th October 2014

Table of Contents

Definitions.....	5
Links to Previous Reports.....	6
GG&C Congenital Anomaly Report for 2012-2013	6
GG&C Congenital Anomaly Report for 2011-2012	6
1. Core Data	7
1.1. Case based review.....	7
1.2. Abnormality based review	10
1.3. Maternal Age	11
1.4. Gender	12
1.5. Multiple Pregnancy	12
2. Point of Diagnosis	13
2.1. At Birth	14
2.2. Within 1 st week	16
2.3. Between 1-4 weeks.....	16
2.4. Diagnosed after 1 month but within 1 year.....	17
2.5. Diagnosis after 12 months	17
2.6. Prenatal Diagnosis.....	17
2.7. Unknown	19
2.8. Post-mortem	19
3. Pregnancy Outcome.....	20
3.1. Live-birth	21
3.2. Stillbirth.....	22
3.3. Spontaneous Fetal Loss.....	23
3.4. Termination of Pregnancy.....	23
4. Review by Defined Abnormality	25
4.1. Endocrine & Metabolic Disorders	25
4.1.1. Congenital Hypothyroidism, (E0310; E0312; E039)	25
4.1.2. Congenital Hyper-insulinism, (E161, E169).....	25
4.1.3. In-born Errors of Metabolism	26
4.1.4. Disorders of Aromatic Amino-Acid Metabolism, (E70).....	26
4.1.5. Disorders of Branched Chain Amino-Acid and Fatty Acid Metabolism, (E71)	26
4.1.6. Other Disorders of Carbohydrate Metabolism	27
4.1.7. Cystic Fibrosis, (E840; E841; E849).....	27

Congenital Anomalies Report 2013-2014

4.2. Cranial & Spinal Abnormalities	28
4.2.1. Neural Tube Defect, (NTD).....	28
4.2.2. Holoprosencephaly, (Q042)	30
4.2.3. Microcephaly, (Q02X)	31
4.2.4. Hydrocephalus, (Q030, Q039).....	32
4.2.5. Other Cranial & Spinal Abnormalities	32
4.3. Cardiac & Circulatory	33
4.3.1. Transposition of the Great Vessels, (Q203)	35
4.3.2. Atrioventricular Septal Defect, (AVSD), (Q212)	35
4.3.3. Fallot's Tetralogy, (Q213).....	36
4.3.4. Pulmonary Valve Atresia & Stenosis, (Q220, Q221)	36
4.3.5. Hypoplastic Left Heart Syndrome, (Q234)	37
4.3.6. Coarctation of the Aorta, (Q251)	37
4.3.5. Total Anomalous Pulmonary Venous Drainage, (TAPVD), (Q262).....	38
4.4. Congenital Malformations of the Respiratory System.....	39
4.4.1. Choanal Atresia, (Q300)	39
4.4.2. Laryngeal Atresia, (Q318).....	39
4.4.3. Congenital Cystic Adenomatoid Malformation, (Q338, Q3380).....	39
4.4.4. Neuroenteric Cysts, Q341	40
4.5. Face & Neck.....	41
4.5.1. Cleft Lip & Palate, (Q 352, Q3539, Q3599, Q3690, Q3699, Q378, Q3799).....	41
4.5.2. Congenital Cavernous Lymphangioma, 'Cystic Hygroma', (D181, D1810).	42
4.5.3. Pierre-Robin Sequence, (Q870)	42
4.5.4. Congenital Cataracts, (Q120)	42
4.5.5. Other Face & Neck	43
4.6. Gastrointestinal Abnormalities	44
4.6.1. Oesophageal Atresia, (Q391)	44
4.6.2. Imperforate Anus, Anal Stenosis & Anorectal Atresia, (Q4200, Q421, Q4290).....	44
4.6.3. Malrotation of Bowel, (Q433).....	45
4.6.4. Other Gastrointestinal Abnormalities.....	45
4.7. Renal & Urinary System	46
4.7.1. Renal Agenesis and Other Reduction Defects, (Q600, Q601, Q602)	46
4.7.2. Cystic Kidney Disease (Q611, Q614, Q6141).....	47
4.7.3. Congenital Obstructive Defects of Renal Pelvis & Malformation of Ureter, (Q62)	47
4.7.4. Other Congenital Malformations of the Kidney, (Q63)	48
4.7.5. Other Congenital Anormalities, (Q64)	49
4.7.6. Hypospadias, (Q540, Q541, Q542, Q549)	50

Congenital Anomalies Report 2013-2014

4.8. Musculo-Skeletal Abnormalities	51
4.8.1. Developmental Dysplasia of the Hip, (Q6580, Q6581)	51
4.8.2. Achondroplasia, (Q774)	51
4.8.3. Talipes Equino Varus, (Q660)	51
4.8.4. Limb Reduction Defects, (Q71, Q72).	52
4.8.5. Craniosynostosis (Q750)	52
4.8.6. Other Musculo-Skeletal Abnormalities.....	52
4.9. Abdominal Wall Defect	54
4.9.1. Congenital Diaphragmatic Hernia, (Q790, Q791)	54
4.9.2. Gastroschisis, (Q793)	54
4.9.3. Exomphalos, (Q792).....	55
4.9.4. Amniotic Band Sequence, (Q7980)	55
4.10. Chromosomal Abnormality	56
4.10.1. Trisomy 21 (Down Syndrome), (Q900, Q909).....	57
4.10.2. Trisomy 18, (Q910).....	58
4.10.3. Trisomy 13, (Q914, Q917)	59
4.10.4. Polyploidy: Triploidy & Tetraploidy, (Q927)	59
4.10.5. Turner Syndrome, (Q960, Q969)	59
4.10.6. Klinefelter Syndrome, (Q980)	59
4.10.7. Other Specified Chromosome Abnormalities, (Q998)	60
Appendix 1	61
NHS Greater Glasgow & Clyde Maternities 1 st April 2013 – 31 st March 2014	61
Appendix 2	62
Case Prevalence Comparison, (per 10,000 births)	62
Appendix 3	63
Prenatal Detection Rates: Comparison with 'established' data	63

Definitions

A **congenital disorder**, or congenital disease, is a condition existing at birth. The disorder may be the result of genetic abnormality, errors of morphogenesis, the intrauterine environment, infection or chromosomal abnormality.

Birth defect is a widely used term for congenital malformation which is recognizable at birth. Congenital anomalies are of four clinically significant types.

- Malformations
- Deformations
- Disruptions
- Dysplasias

Malformation: In a malformation the development of a structure is arrested delayed or misdirected early in embryonic life and the effect is permanent.

Deformations: Are distinct from malformations in both timing and impact. They are conditions that arise from the application of mechanical stress to normally formed tissues. They may occur later in pregnancy and can be temporary.

Disruptions: Describes a complete breakdown of normal tissues

Dysplasias: Cellular abnormality of the originating tissue e.g. expansion of immature cells with a corresponding decrease in the number and location of mature cells.

Congenital disorders may consist of more than one abnormality. When multiple effects occur in a specified order the disorder is known as a **sequence**. When the order is not known it is called a **syndrome**.

BINOCAR: The British Isles Network of Congenital Anomaly Registers. A group of regional disease specific registers collecting information about congenital abnormalities occurring in England, Ireland, Scotland & Wales. BINOCAR was set up jointly, in 1996, by the Office for National Statistics and Dr. David Stone at the Glasgow Register of Congenital Anomalies

EUROCAT: European Surveillance of Congenital Anomalies. A study based on a network of population based registries for the epidemiological surveillance of congenital anomalies. It was established in 1979 as one of the first Concerted Action Research Programmes funded by the European Commission and surveys more than 1.7M births per year in Europe.

Incidence or Birth Prevalence? The incidence is the rate of occurrence of new cases of a disease or condition over a specified period of time expressed as a ratio or percentage.

$$\text{Incidence} = \frac{\text{number of new cases over specified period of time}}{\text{size of population under consideration}}$$

In previous reports **incidence** has been used in preference to **prevalence**, which describes how frequently a disease or condition occurs in a specified population at a particular point in time.

The appropriate denominator for calculation of the incidence, (the size of the population under consideration who are initially disease free), is debatable. In the circumstances of this study it should

be the number of maternities booked through antenatal services over the year 1st April 2013 and 31st March 2014, (Appendix 1).

All congenital anomaly registers report the number of babies with anomalies born during a calendar year. Perhaps this should mean that they would all report incidence rates. However in practice the majority of congenital anomaly registers actually report prevalence estimates.

The reason given is that it is not possible to ascertain all 'new' cases of any particular anomaly as a proportion of pregnancies affected with an anomaly will miscarry spontaneously before being diagnosed. Indeed, although 16,312 women booked with NHS GG&C between 1st April 2013 and 31st March 2014, a total of 18,355 appointed referrals were made during the same time period. This means that at least 2,043 pregnancies were 'lost' from time of referral to booking, (Appendix 1).

As a consequence congenital anomaly registers, such as EUROCAT and BINOCAR, report prevalence estimates per 1,000 or 10,000 total births, (live and stillbirths). These are referred to as birth prevalence estimates even though the pregnancy may not result in a 'birth' because of late miscarriage or termination of pregnancy for fetal anomaly, (fetal loss less than 20 weeks gestation is excluded from prevalence data).

Prenatal Diagnosis: A diagnosis of abnormality made in a live fetus at any gestation.

Prenatal Screening: Test for identifying a fetus that may be at a high risk for a defined congenital abnormality such as Down syndrome.

Stillbirth: Late fetal deaths from 24 completed week's gestation.

Termination for fetal anomaly: Deliberate ending of pregnancy, with intention that the fetus will not survive, following the prenatal diagnosis of major congenital anomaly

Links to Previous Reports

Previous reports are available on-line for download through the GG&C Public Health Screening website:-

GG&C Congenital Anomaly Report for 2012-2013

http://library.nhsggc.org.uk/mediaAssets/Public%20Health%20Screening/CongenitalAnomaly2012-2013_FinalDraft.pdf

GG&C Congenital Anomaly Report for 2011-2012

<http://library.nhsgg.org.uk/mediaAssets/Public%20Health%20Screening/Review%20of%20Congenital%20Anomalies%20J%20Robins%202013.pdf>

Please Note:

The report from 2010-2011 is currently not available on-line.

1. Core Data

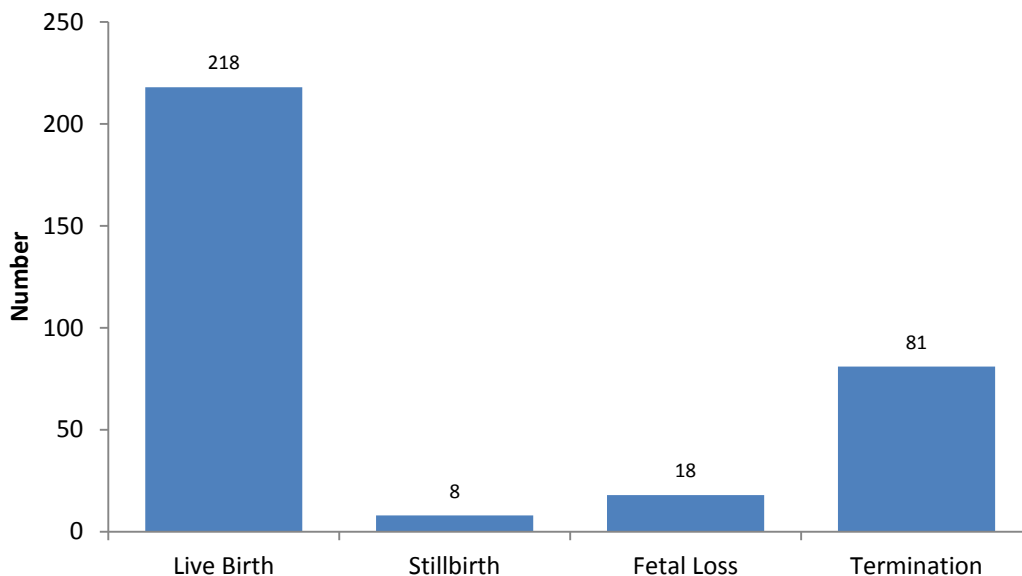
This report considers all live-births, stillbirths, fetal losses and terminations of pregnancy between 1st April 2013 and 31st March 2014 that were associated with one or more congenital abnormalities. Congenital anomaly data are collected from a number of different sources. The contents of the report are merely a 'snapshot'. The data set is constantly updated as further congenital abnormalities are recognized within the cohort.

1.1. Case based review

A total of 325 cases were identified from 325 pregnancies. This gives a case rate for congenital anomaly of 244/10,000 live and stillbirths¹. This is slightly less than reported for the 2012-2013 cohort but does not imply any 'improvement' in numbers of congenital anomaly. The data taken to compile this current report has been extracted a little earlier than for previous reports.

The majority of cases were live-births, (n=218, 67%). There were 8 stillbirths (2%) and 18 fetal losses (6%). Termination of pregnancy following prenatal diagnosis of abnormality accounted for 81 cases, (25%), (Figure 1.1).

Figure 1.1: Pregnancy Outcome, (n=325).



Overall a total of 558 abnormalities were classified in these 325 cases using the ICD10 system, the primary abnormality and a variable number of associated abnormalities. In 209 cases only the primary abnormality is listed. However in 116 cases, (36%), two or more abnormalities have been classified, (Figure 1.2). In two cases a total of 8 abnormalities were defined.

The data on the 325 cases, including associated abnormalities, has been provided as a list which has been ordered on the basis of the primary abnormality as defined under ICD10, (Figure 1.3). Additional information has also been collected on gestational age at time of birth or termination, gestational age at 'point of diagnosis' if antenatal, maternal age, birth order for multiple pregnancy and gender. Further supporting data has been made available from the Pregnancy & Newborn Screening data base, (PNBS).

¹ This is calculated from the number of live and still births for GG&C for the time period 1st April 2013 to 31st March 2014 which is 13,321, (GRO Births & Stillbirths Data extract at 9th July 2014).

Figure 1.2: Abnormalities per case, (n=325).

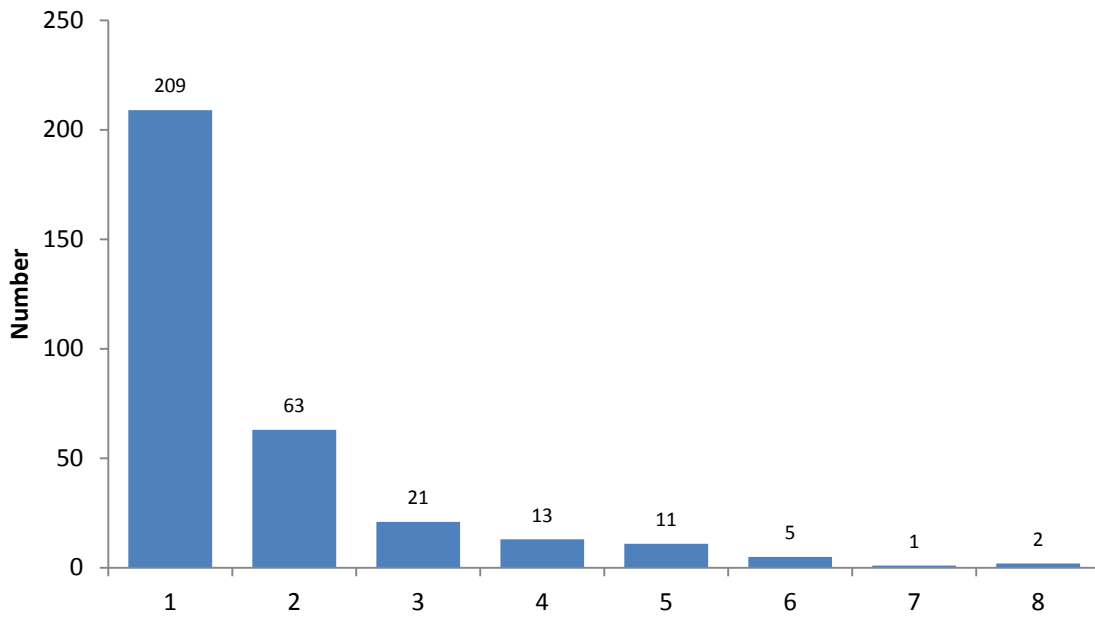
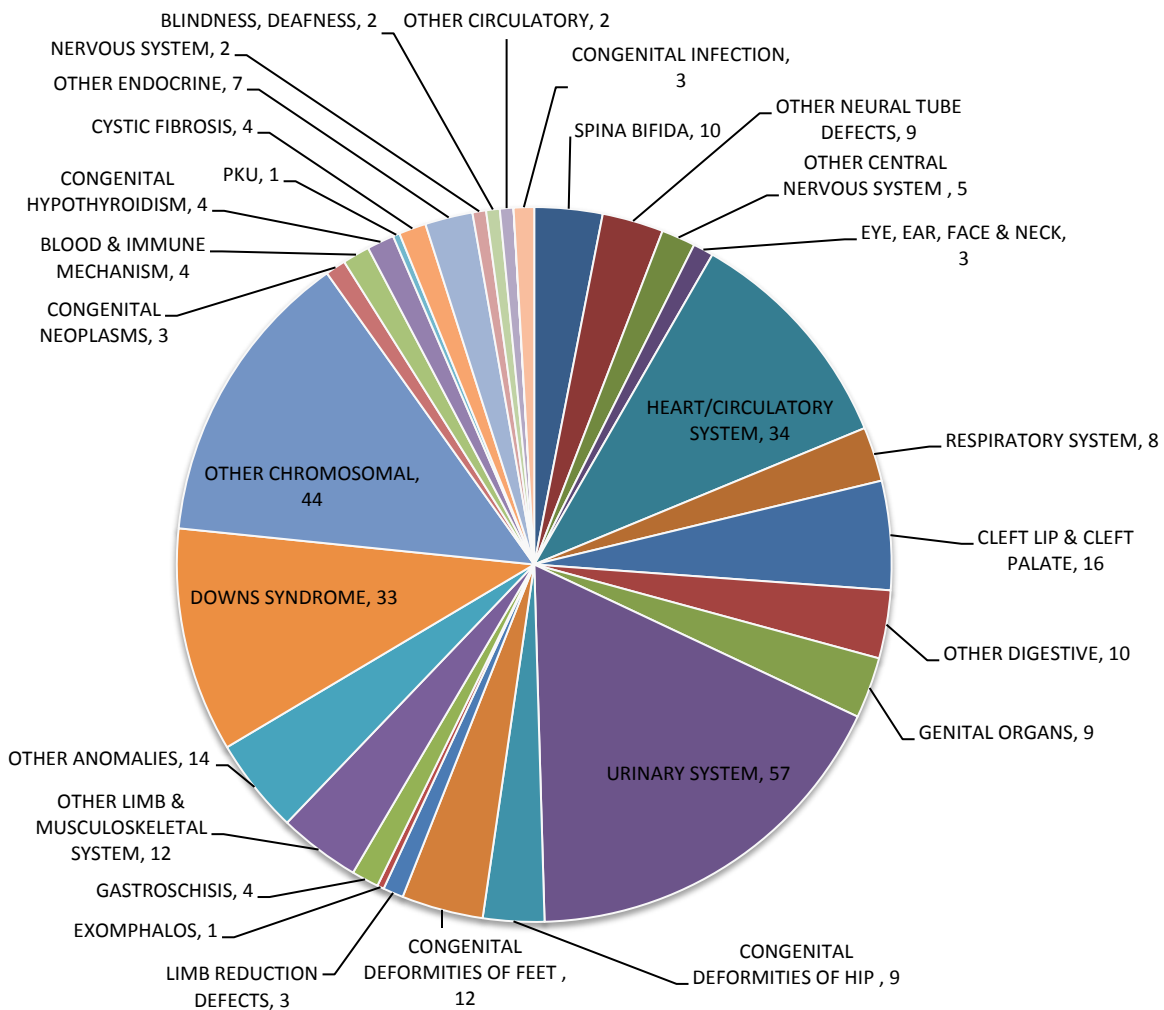


Figure 1.3: Classification according to Primary Abnormality (ICD10), (n=325).



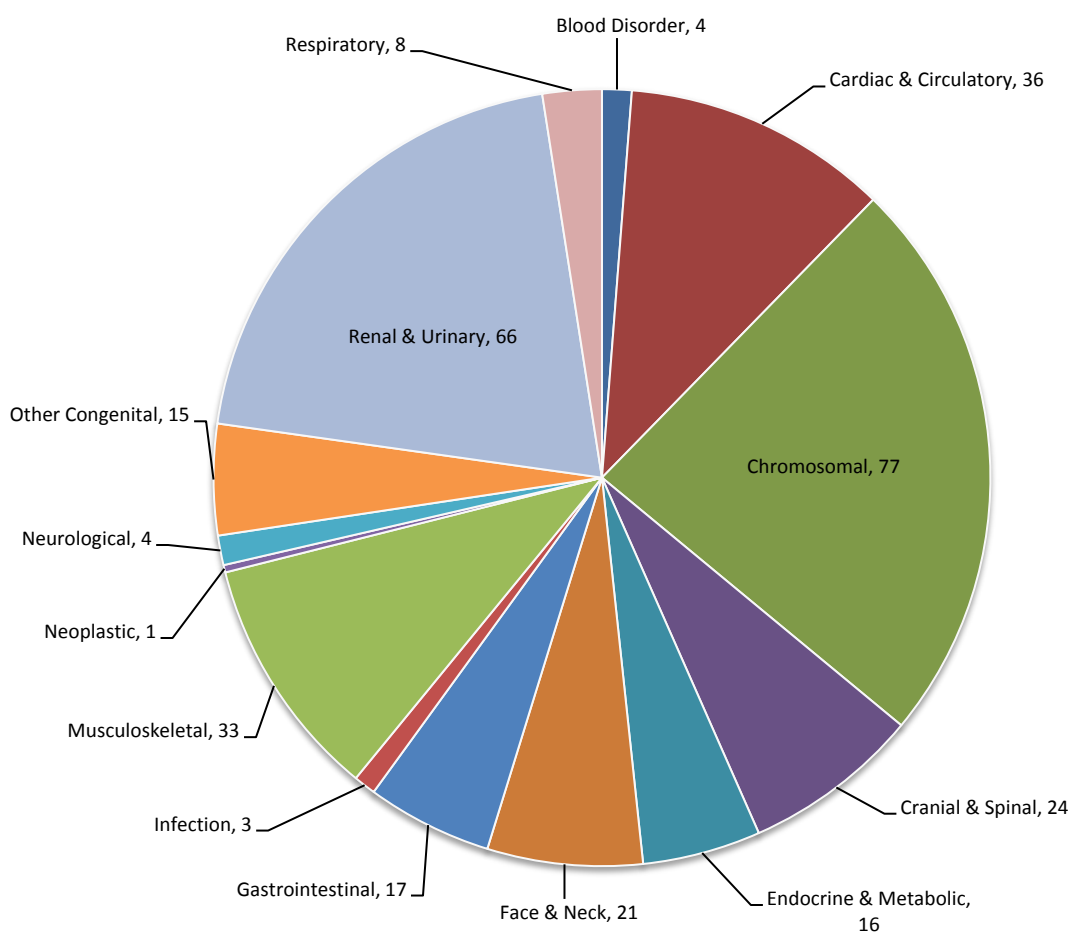
Chromosomal abnormality, ('Down Syndrome' and 'Other Chromosomal Disorders'), is the most common primary classification accounting for up to 23.7% of cases, (n=77). Congenital anomalies of the Genitourinary system, ('Genital Organs' and 'Urinary System'), are the next most common primary abnormality, (n=66; 20.3%).

There are a total of 41 cases where a primary abnormality of the musculoskeletal system, ('Congenital Deformities of Hip', 'Congenital Deformities of Feet', 'Limb Reduction Defects' and 'Other Limb & Musculoskeletal System'), is classified under ICD10. This number also includes congenital diaphragmatic hernia, exomphalos, gastroschisis and amniotic band sequence.

Disorders of the Heart and Circulatory System, ('Circulatory System' and 'Other Circulatory'), are classified as the primary abnormality in a total of 36 cases, (11.1%). Cranial and spinal abnormality, ('Spina Bifida', 'Other Neural Tube Defects' and 'Other Central Nervous System'), is the preferred primary classification in 24 cases, (7.3%).

Clearly some disorders, as classified and ordered under ICD10, are typically reviewed under other 'systems' and hence an aggregated and simplified chart based on primary abnormality is presented in Figure 1.4. For example in the 'simplified' classification exomphalos and gastroschisis are included as abnormalities of the gastrointestinal rather than musculoskeletal system.

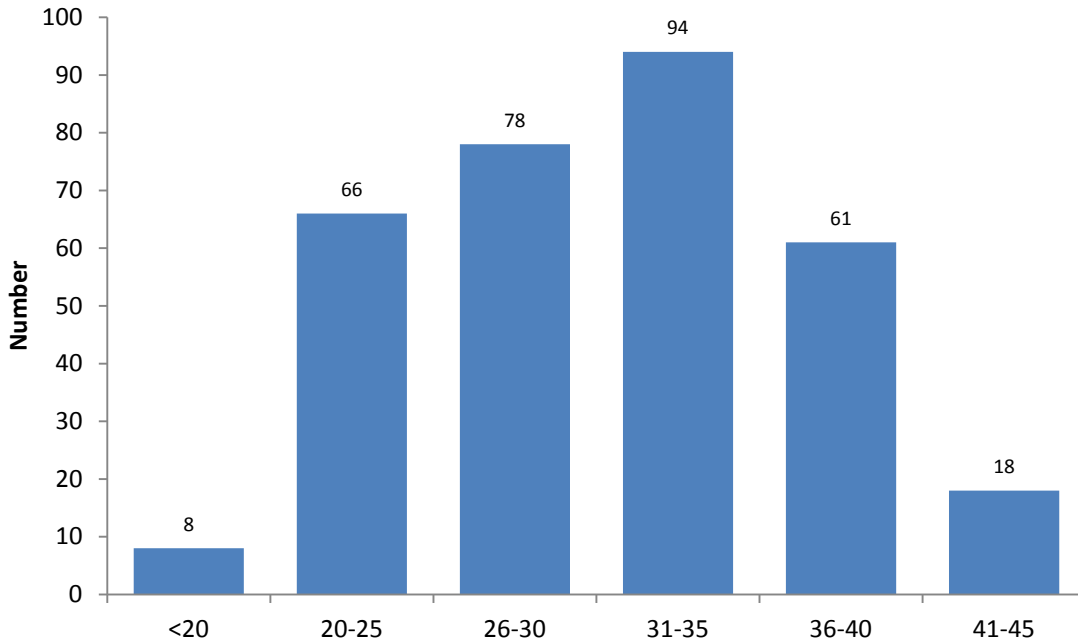
Figure 1.4: Simplified Classification by Primary Abnormality, (n=325).



1.3. Maternal Age

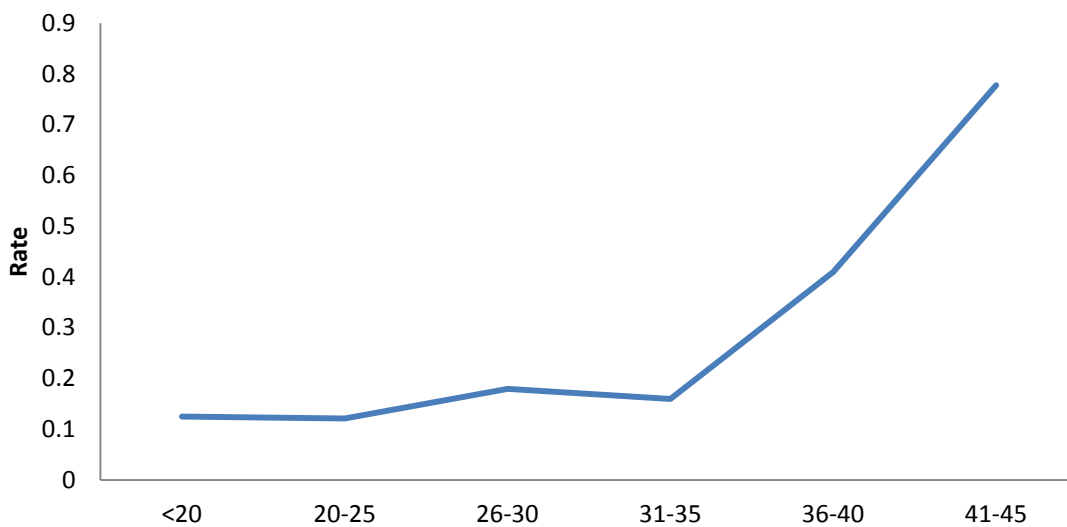
Overall 325 pregnancies accounted for the 325 classified cases of abnormality. Maternal age at time of delivery, miscarriage or termination ranged from 17 to 45 years, (Figure 1.6). The mean age was 30.8 years. Although maternal age is recorded in the register no information is held on paternal age.

Figure 1.6: Maternal age at delivery or loss, (n=325)



Data from BINOCAR would suggest that mothers under the age of 20 years have the highest prevalence of non-chromosomal anomalies when compared with older mothers whereas the birth prevalence of chromosomal anomalies increases with age. Rudimentary analysis of GG&C data for 2013-2014 confirms a higher rate of chromosomal abnormalities in older mothers, (Figure 1.7).

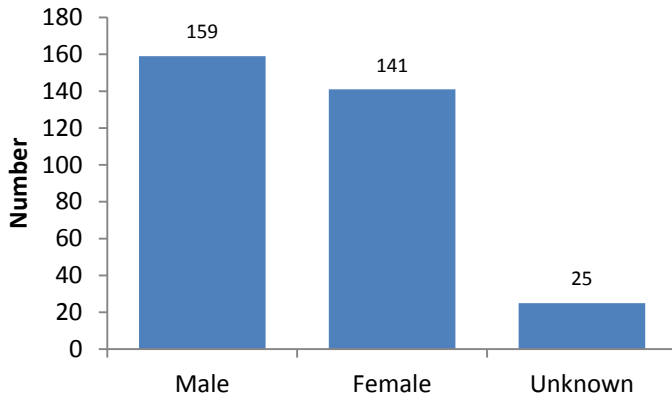
Figure 1.7: Rate of primary chromosomal abnormality as proportion of all primary abnormalities within each given maternal age group (years).



1.4. Gender

Gender is given for 300 cases. Congenital abnormality was slightly more prevalent in males than females, (ratio 1.12:1). In the remaining 25 cases gender is recorded as unknown, (Figure 1.8).

Figure 1.8: Fetal & Infant Gender, (n=325)



The mean gestation at delivery for cases of 'unknown' gender is 15.5 weeks. They were either terminations, (n=21), or early spontaneous fetal losses, (n=4). In all but one case a prenatal diagnosis of abnormality was made. Six cases were terminated following the prenatal diagnosis of chromosomal abnormality so it is likely that the genetic sex will be known.

1.5. Multiple Pregnancy

Eight cases are recorded from twin pregnancies. All were live births, (mean gestation at delivery 36.5 weeks). In each case the co-twin showed no evidence of congenital abnormality.

Q205	CONGENITALLY CORRECTED TGA	Prenatal diagnosis; Female; 2 nd twin
Q213	TETRALOGY OF FALLOT	Anal atresia with fistula; male; 2 nd twin
Q234	HYPOPLASTIC (L) HEART	Prenatal diagnosis
Q6580	DDH ®	Female; 2 nd twin; Diagnosis 1-12 months
Q660	TEV - BILAT	Male; 1 st twin
Q660	CTEV ®	Male; 2 nd twin
Q8706	MOEBIUS SYNDROME	Prenatal diagnosis; Bilateral talipes
Q8710	AARSKOG-SCOTT SYNDROME	Prenatal diagnosis; Male; 2 nd twin; hypospadias

Moebius syndrome is a rare condition with paralysis of the VIth and VIIth cranial nerves leading to expressionless facial features, limitation of tongue movement, feeding difficulties, speech defect, and ptosis. Skeletal defects such as limb hypoplasia, webbing of the digits and rib defects are also common as is a degree of developmental delay³.

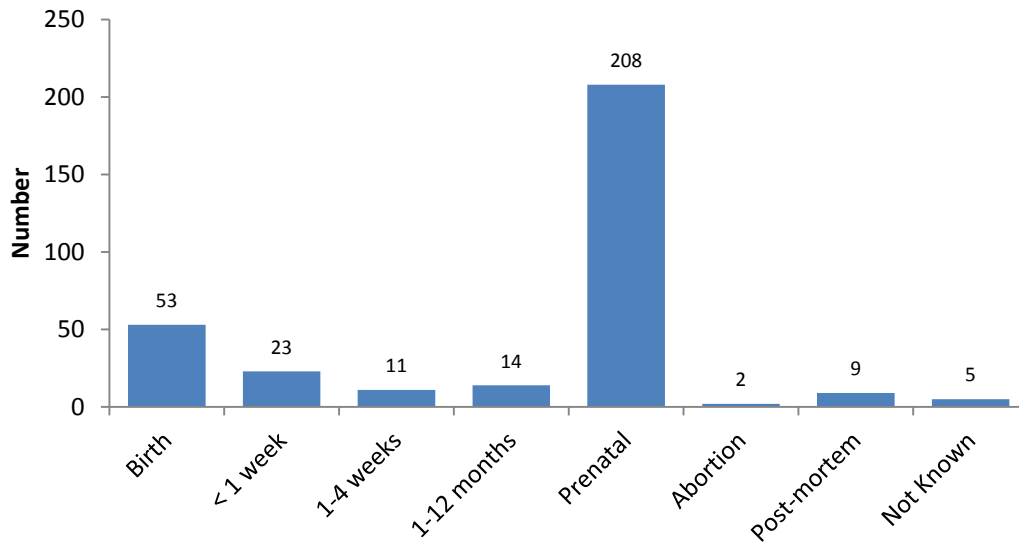
Aarskog-Scott syndrome is also very rare. First described in 1970's it is an X-linked recessive disorder characterized by short stature with facial, genital and skeletal anomalies. Females may have milder features. Prevalence is said to be in the order of 1:1,000,000 births but mildly affected individuals may not be identified and so the incidence may be higher. Diagnosis is typically based on recognition of the distinctive pattern of craniofacial anomalies, short stature, urogenital abnormalities and shortening of distal extremities.

³ It is unlikely that the diagnosis of Moebius syndrome was achieved on prenatal scan. However bilateral talipes would have been evident on ultrasound and it is this that defines the point of diagnosis, (see next).

2. Point of Diagnosis

Data are available for the ‘point of diagnosis’, or ‘date of discovery’ if it is preferred, (Figure 2.1). It should however be clear from the example given above that this does not necessarily imply the point at which the primary abnormality was first recognized and some care must be exercised in interpreting the data. Under EUROCAT definitions the ‘point of diagnosis’ or ‘date of discovery’ is the date on which the fetus or infant is first suspected or recognized as being malformed, even if a detailed diagnosis is not available.

Figure 2.1: Point of Diagnosis for Primary Abnormality, (n=325)



Over 64%, (n=208), of primary abnormalities were diagnosed prenatally. In 76 cases, (23.4%), the diagnosis was made at birth or within the first week of life. Fourteen cases, (4.3%), were diagnosed after the first month but within 1 year. Nine cases, (2.7%), were diagnosed at post-mortem. In a further 5 cases the point of diagnosis is recorded as ‘unknown’.

A chart demonstrating Point of Diagnosis for primary abnormality, as defined by the ‘simplified’ classification described above, is produced, (Figure 2.2).

Typically most diagnoses of primary abnormality are made either antenatally or within the first week of life. Eighty-four percent of all ‘Cranial & Spinal’ abnormalities, eighty-two percent of ‘Renal & Urinary’ abnormalities and seventy-four percent of ‘Chromosomal’ abnormalities are diagnosed prenatally. The only lesion classified as ‘Neoplastic’, a posterior fossa brain tumour, was a prenatal diagnosis.

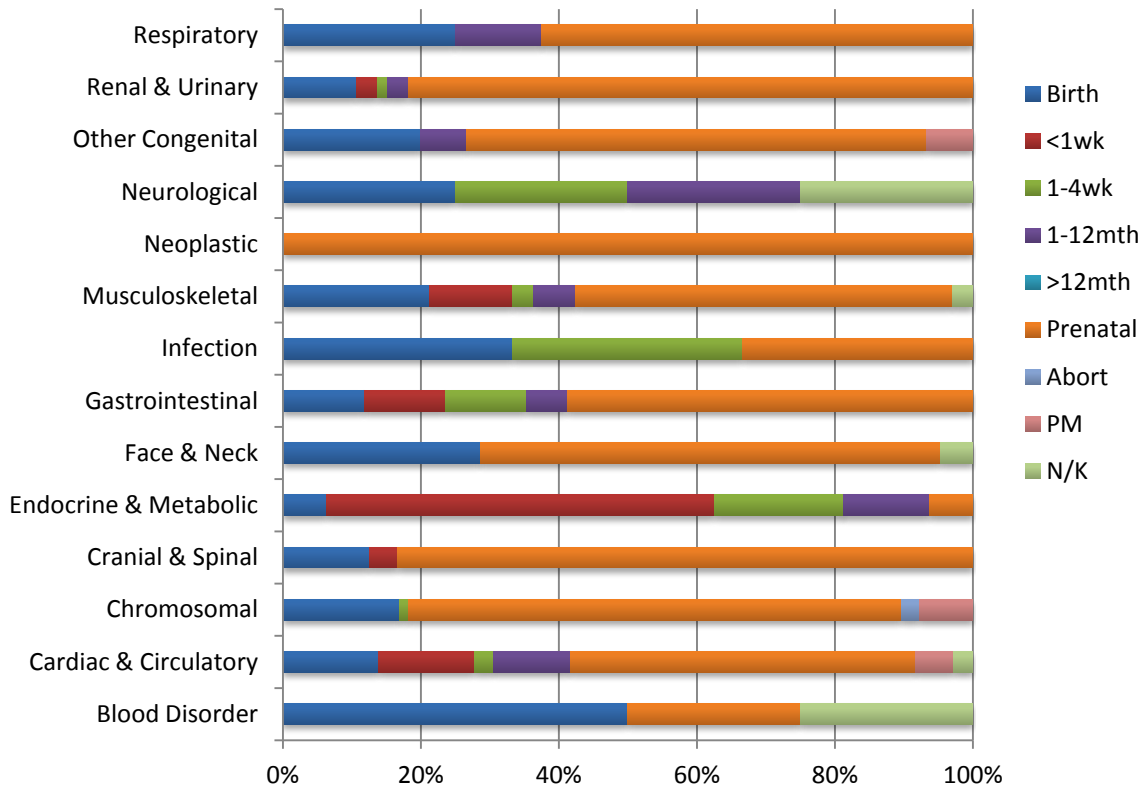
The results of routine blood spot analysis dictate that ‘Endocrine & Metabolic’ disorders will usually be diagnosed around 1- 4 weeks.

Although the majority of primary ‘Cardiac & Circulatory’ disorders are picked up either on antenatal scan or during the first week of life, a proportion, (11%), are not diagnosed until 1 – 12 months of life. This is also true of ‘Neurological’ disorders although the numbers are much smaller.

There were four cases of primary ‘Blood Disorder’. Two of these were cases of severe Haemophilia A diagnosed at birth. A case of Fanconi’s anaemia, associated with the typical reduction defects of the upper limbs, was diagnosed prenatally and terminated. The remaining case was one of Di George

syndrome which is considered later because the point of diagnosis is recorded as 'unknown', (although most likely to have been at birth).

Figure 2.2: Point of Diagnosis for Main ICD10 Category, (Simplified), (n=325)



2.1. At Birth

Fifty-three primary abnormalities are coded as being diagnosed at birth, (Figure 2.3).

Chromosomal disorders again comprise the largest group, (n=13, 24.5%). Eleven cases of Trisomy 21 were diagnosed at birth. Further information extracted from the Pregnancy & Newborn Screening Programme database reveals that out of these eleven cases, two women had declined Down syndrome screening, two had been screened as high risk but declined invasive testing, six had been found to be low risk on screening and the remaining case was a late antenatal booker.

Hypospadias accounted for six of the seven 'Renal & Urinary' system diagnoses made at birth, (all male). The other case was one of a patent urachus in a term male infant.

Abnormalities of the 'Face & Neck' first diagnosed at birth included an extensive left sided nuchal lymphangioma in a preterm male infant, two cases of congenital cataracts, two cases of isolated cleft palate and a right sided branchial remnant seen in a female infant delivered at term.

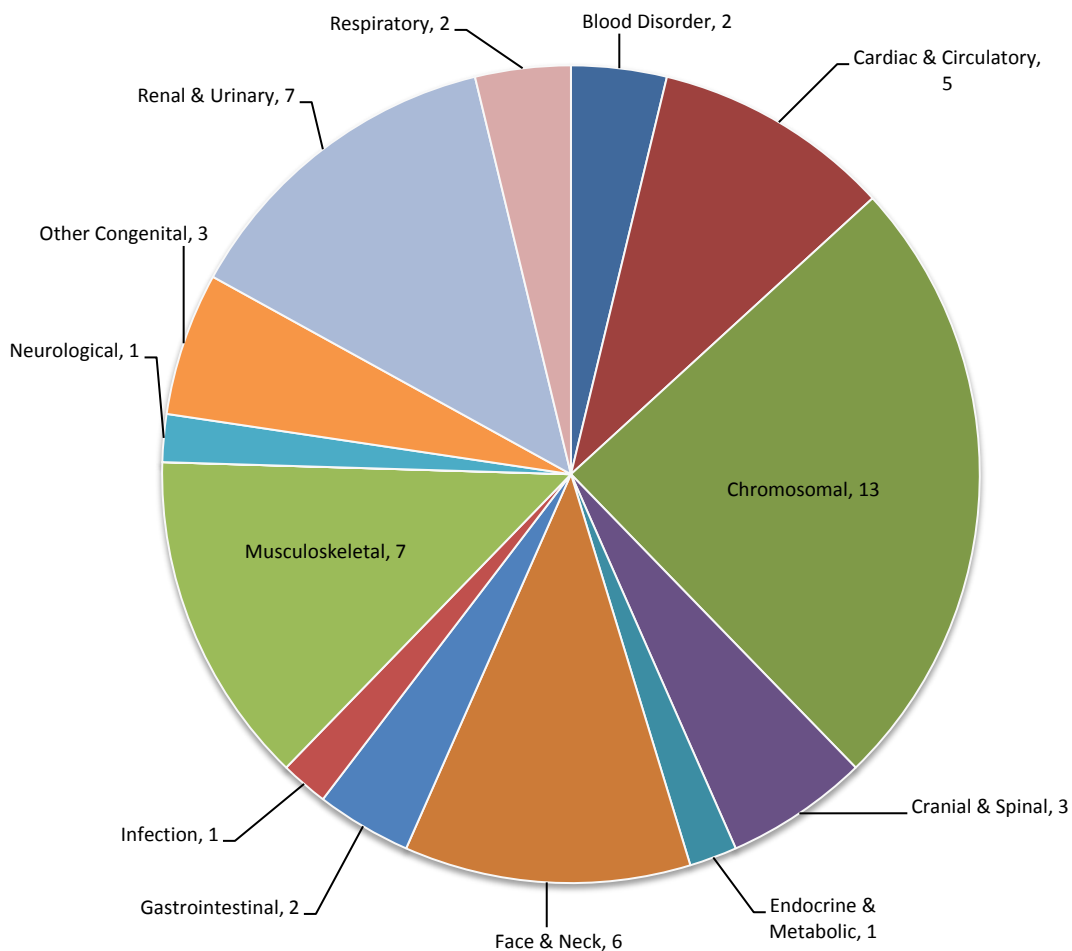
Cardiac abnormalities diagnosed at birth included pulmonary valve stenosis, total anomalous pulmonary venous drainage and two cases of Tetralogy of Fallot. A male infant delivered at term was also found to have a persistent supra-ventricular tachycardia (SVT) and posterior urethral valves.

Congenital cytomegalovirus (CMV) infection was diagnosed shortly after birth in a male infant delivered at term. No associated features are noted. CMV is the most common congenital infection

in the UK. Intrauterine transmission occurs in 25-50% of primary maternal infections. Some 10% of infected fetuses show severe CNS involvement with features such as mental retardation, microcephaly, hydrocephalus, and deafness. Hepatosplenomegaly and petichiae are common. There are often no clinical clues to an at risk pregnancy. Like herpes simplex virus, cytomegalovirus also shows the property of latency and recurrence is not unknown in subsequent pregnancy, although the risk of having a second congenitally infected child is low.

A case of Type 1 Spinal Muscular Atrophy (SMA), a severe neurological condition, was also diagnosed at birth in a female infant. Spinal Muscular Atrophy Types I, II, and III belong to a group of hereditary diseases that cause weakness and wasting of the voluntary muscles in the arms and legs of infants and children. The disorders are caused by an abnormal or missing gene known as the survival motor neuron gene 1 (SMN1). As a consequence lower motor neurons in the spinal cord degenerate and die. Type I (also known as Werdnig-Hoffman disease) is typically evident at birth or within the first few months. Symptoms include floppy limbs and trunk, feeble movements of the arms and legs, swallowing and feeding difficulties, and impaired breathing. The prognosis is poor for babies with SMA Type I.

Figure 2.3: Diagnosis made at Birth by Primary Abnormality, (Simplified), (n=53)



2.2. Within 1st week

Congenital abnormality was diagnosed in 23 cases during the first week of life. Endocrine and metabolic abnormalities predominate and account for 39.1% of all diagnoses made in the first week of life, (n=9). There were three cases of congenital hypothyroidism and a further three cases of cystic fibrosis. Other diagnoses within this category were congenital hyperinsulinism and phenylketonuria.

There were five cases classified as having an abnormality of the cardiac and circulatory system. These were cases of congenitally corrected TGV, pulmonary stenosis, aortic valve stenosis, coarctation of the aorta and dysplastic aortic valve.

A diagnosis of microcephaly was made in a female infant delivered at term. There were no associated abnormalities.

Four cases, (all female), were related to the diagnosis of developmental dysplasia of the hips, (DDH).

A male infant, delivered at term, was found to have a number of abnormalities including imperforate anus, a prostatic-urethral fistula, posterior urethral valves and an unspecified congenital malformation of the spine. Two further cases of hypospadias, one severe, were also confirmed

The remaining case was one of malrotation of the gut in a male infant. There were no associated abnormalities

2.3. Between 1-4 weeks

Overall 11 cases are recorded as being diagnosed with 1 and 4 weeks. As expected a number of disorders are still being picked up as a result of routine newborn screening processes including sensorineural deafness as well as endocrine and metabolic disorders.

E039	CONGENITAL HYPOTHYROIDISM	Female infant
E742	GALACTOSAEMIA - GALT DEFICIENCY	Male infant
E840	CYSTIC FIBROSIS	Talipes
H903	CONGENITAL SENSORINEURAL DEAFNESS	Female infant
P358	CONGENITAL VARICELLA	Cataract; Microcephaly
Q262	TAPVD	
Q431	HIRSCHSPRUNG'S DISEASE	
Q431	HIRSCHSPRUNG'S DISEASE	Malrotation of gut
Q600	RENAL AGENESIS (L)	
Q6580	DDH (L)	
Q928	MOSAIC TRISOMY FOR A PARTIAL RING 14 CHROMOSOME	TAPVD; VSD

Hirschsprung's disease typically presents with abdominal distension and failure of passage of meconium within the first 48 hours following delivery.

A ring chromosome is a circular structure that occurs when a chromosome breaks in two places and its ends fuse together. Several critical genes near the end of the long (q) arm of chromosome 14 are lost when the ring chromosome forms. The loss of these genes can lead to intellectual disability and delayed development. Epilepsy is a common feature of ring chromosome syndromes. The case described was a male infant delivered at term to an older mother.

2.4. Diagnosed after 1 month but within 1 year

There were a total of 14 cases in which the primary abnormality was diagnosed after 1 month but within 1 year.

E703	ALBINISM - OCULOCUTANEOUS	Male
E713	MCAD DEFICIENCY	Male
G120	SMA TYPE 1	Female
I420	DILATED CARDIOMYOPATHY	Female
Q250	PDA	Female
Q250	PDA	Female
Q256	PULMONARY ARTERY STENOSIS - (L) BRANCH	Male; Preterm delivery at 36 weeks
Q300	CHOANAL ATRESIA (L)	Female; Preterm delivery at 26 weeks
Q540	HYPOSPADIAS - CORONAL	Male
Q630	DUPLEX KIDNEY (L)	Female
Q6580	DDH ®	Female
Q6580	DDH ®	Female
Q790	DIAPHRAGMATIC HERNIA	Male
Q899	UNDIAGNOSED GENETIC SYNDROME	Female; Multiple abnormalities

Just over a quarter of cases, (n=4), were cardiac or circulatory in origin with two cases relating to persistence of a patent ductus arteriosus in term infants.

Endocrine and metabolic disorders are still being defined and diagnoses of developmental dysplasia of the hips are still being made.

A further case of Type I Spinal muscular atrophy (Werdnig-Hoffman disease) is seen as a later diagnosis, (Part 2.1, Page 15).

2.5. Diagnosis after 12 months

No diagnoses after 12 months are recorded for this cohort. For the compilation of this report an extract has been taken a little earlier than for previous annual reviews. The data set for the 2013-2014 continues to develop and evolve. Further diagnoses will continue to be made and this data set will increase over and above that presented in this current report.

2.6. Prenatal Diagnosis

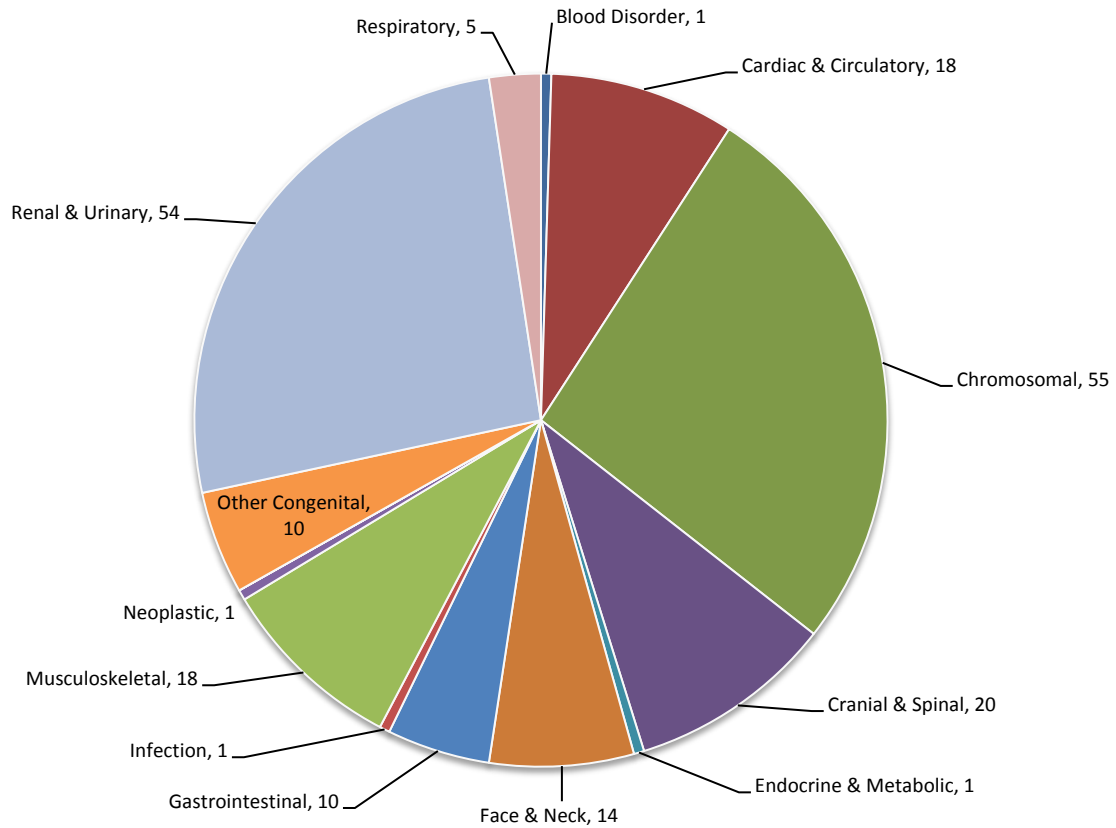
The majority of primary abnormalities were diagnosed during the antenatal period, (n=208, 64%), (Figure 2.4).

Fifty-five cases were associated with chromosomal abnormality of which the majority, (n=22, 40%), were Down syndrome. There were also sixteen cases of Trisomy 18, five cases of Trisomy 13 and a further five cases of Turner syndrome.

The next largest grouping relates to disorders of the 'Renal & Urinary' system. Renal agenesis, either bilateral or unilateral, was an antenatal diagnosis on fourteen occasions. There were eight cases of multicystic dysplastic kidney disease. Congenital hydronephrosis, usually left sided was seen in seven cases. Other abnormalities included duplex kidney, (n=9), ectopic kidney, (n=1), congenital hydronephrosis, (n=7) and posterior urethral valves, (n=2).

Ninety-one percent of all neural tube defects, (anencephaly, spina bifida and encephalocele), were diagnosed on prenatal scan.

Figure 2.4: Prenatal Diagnosis by Primary Abnormality (Simplified Classification), (n=208)



Cardiac and circulatory disorders diagnosed on antenatal scan included hypoplastic left heart, (n=4), Tetralogy of Fallot, (n=6), pulmonary atresia (n=1) and coarctation of the aorta, (n=1).

Primary disorders of the gastrointestinal system subject to prenatal diagnosis included four cases of gastroschisis and one case of exomphalos. Isolated duodenal atresia was picked up in two cases.

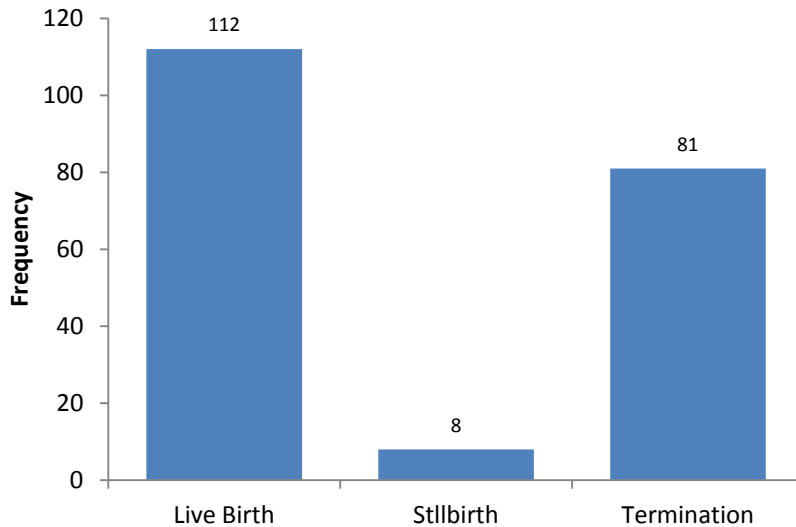
Cleft lip (with or without an associated cleft palate) accounted for the majority, (n=13) of abnormalities of the face and neck detected by prenatal scan. The remaining case was of a right sided lymphangioma of the neck and jaw which was picked up at 36 weeks gestation.

Talipes equino varus accounted for more than fifty-six percent of prenatal diagnoses of musculoskeletal abnormality. Arthrogryposis, achondroplasia, and limb reduction defects were also diagnosed by ultrasound examination.

The finding of significant upper limb reduction defects was the likely precursor to the diagnosis of Fanconi's anaemia, (Part 3.4, Page 23).

Where a prenatal diagnosis of abnormality was made eighty-one cases were terminated, (38.9%), but in the majority of cases, (n=112; 53.8%) the pregnancy continued to live-birth. Eight cases, (3.8%), were stillborn following prenatal diagnosis of congenital abnormality, (Figure 2.5).

Figure 2.5: Outcome of pregnancies in which there was prenatal diagnosis of abnormality, (n=208)



2.7. Unknown

There were five cases in which the point of diagnosis is recorded as 'unknown'. All were live-born and it is likely that diagnosis of abnormality was made soon after birth.

D821	DI GEORGE SYNDROME	Tetralogy of Fallot
H903	BILAT SEVERE SENSORINEURAL HEARING LOSS	
Q245	AORTOPULMONARY COLLATERAL VESSEL FORMATION	Preterm at 25 weeks
Q356	CLEFT PALATE - MIDLINE SOFT	
Q6580	DDH ®	Term female infant

2.8. Post-mortem

There were nine cases where the diagnosis has been recorded as having been made at post-mortem. All were associated with fetal loss, (gestational age range of 9 - 20 weeks). Fetal aneuploidy predominates as a diagnosis, (66.6%).

Q2115	SINGLE ATRIUM	Congenital malformation of pulmonary artery
Q2510	COARCT AORTA - PRE-DUCTAL	
Q893	SITUS INVERSUS	Malrotation of gut
Q910	TRISOMY 18	
Q969	TURNER SYNDROME, (XO)	
Q998	TRISOMY 15	
Q998	TRISOMY 16	
Q998	TRISOMY 15	Klinefelter 47, XXY
Q998	TRISOMY 15	

3. Pregnancy Outcome

A pregnancy outcome is recorded for all 325 cases. The majority of cases were live-born, (Figure 3.1 and Figure 3.2).

Figure 3.1: Pregnancy Outcome, (n=325).

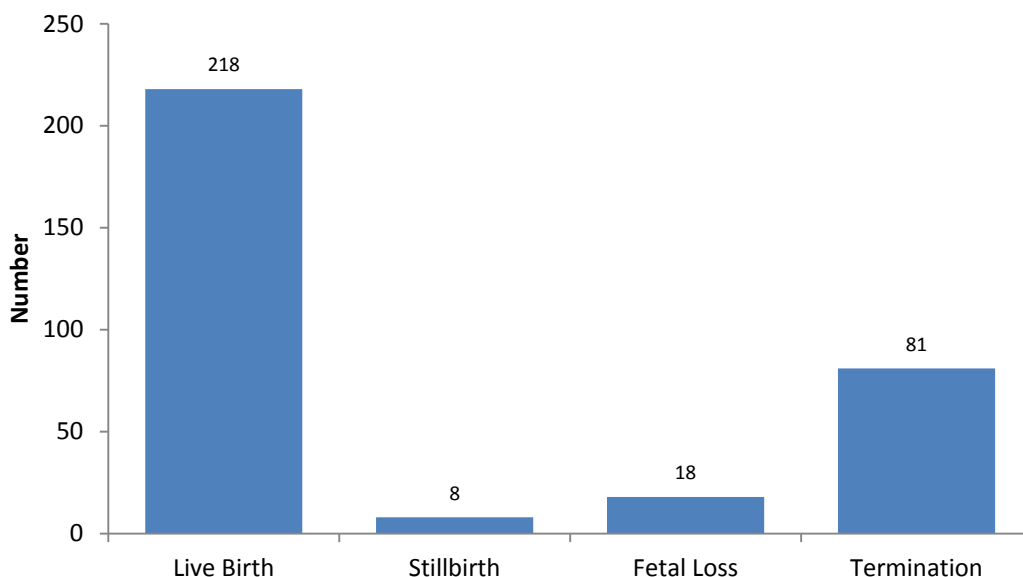
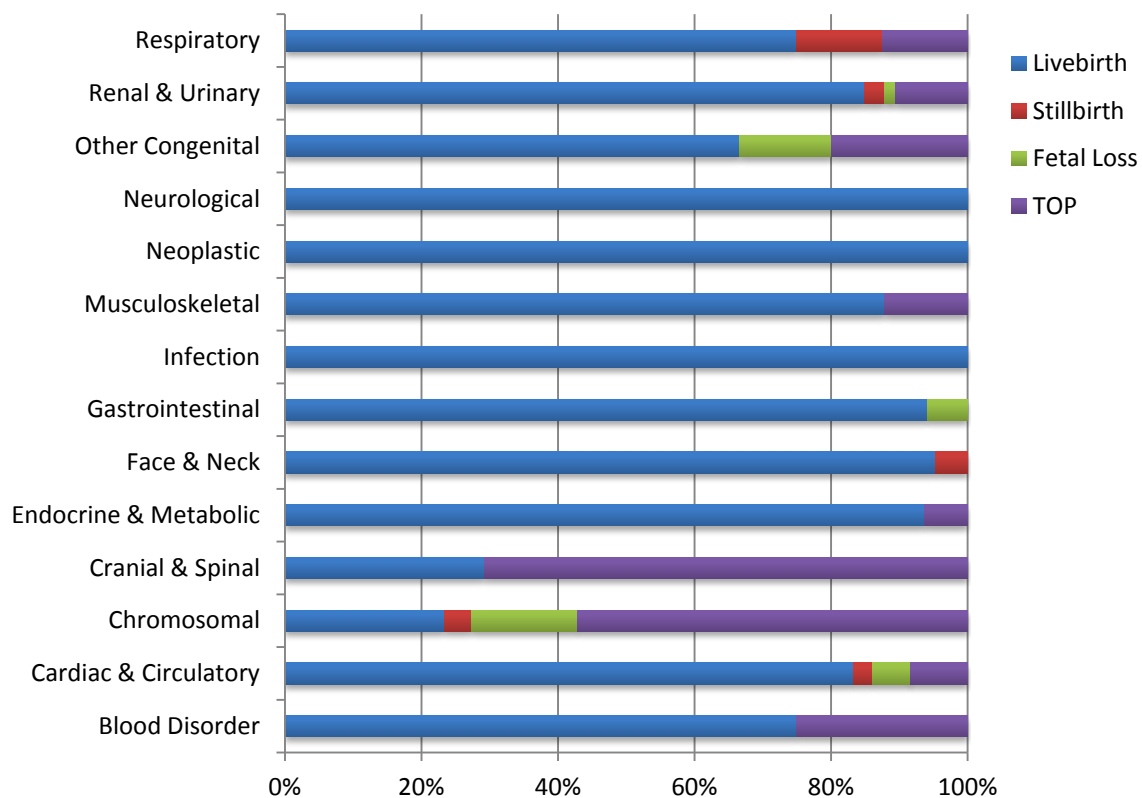


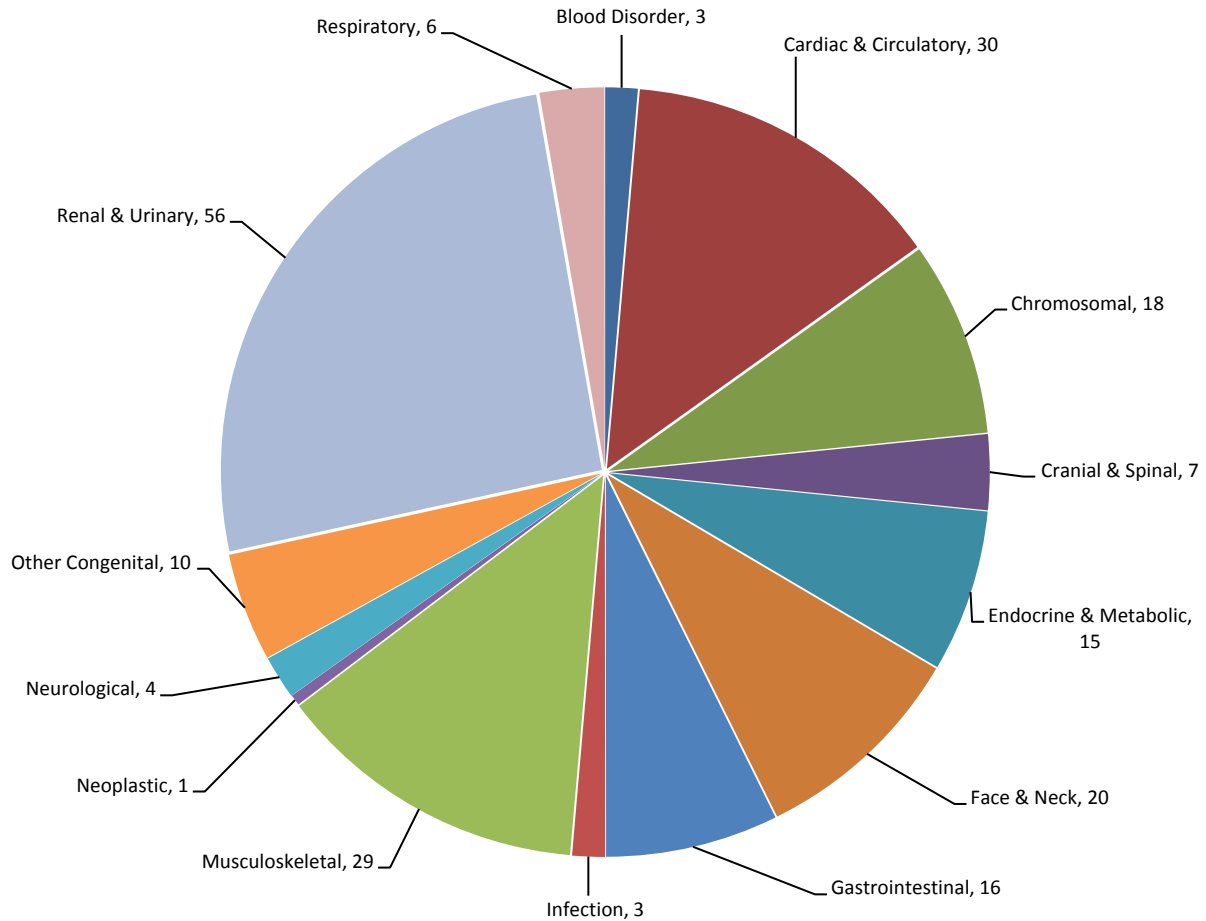
Figure 3.2: Outcome by simplified classification, (n=325).



3.1. Live-birth

Live-birth was the documented outcome for 67% of cases, (n=218), (Figure 3.3). The mean gestation at delivery was 38.4 weeks, (range 25 to 42 weeks).

Figure 3.3: Live-birth by Primary Abnormality (Simplified Classification), (n=218)



Diagnosis was made at birth for 24% of cases, (n=53), (Figure 3.4). Prenatal diagnosis of the primary abnormality was achieved for 51%, (n=112), of live-born infants.

Among the 'Cranial & Spinal' abnormalities were two cases, both in male infants delivered at term, where a disorder of the spine was associated with a fibrolipoma. In one case a fibrolipoma was associated with diastematomyelia and in the other the cord was tethered with a fibrolipoma of the filum terminale.

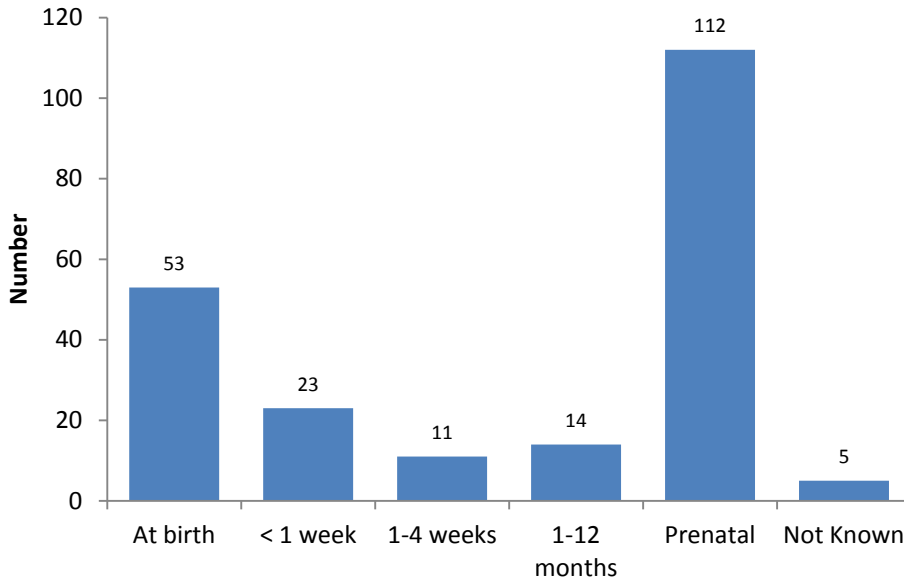
Three infants were born with congenital blood disorder: There were two cases of Haemophilia A, Factor VIII deficiency diagnosed in term male infants, with both classified as severe disorders. The remaining abnormality was a case of Di George syndrome which is classified under ICD10 as a primary haematological disorder.

The ICD10 code of Q828 is used to describe 'Other Specified Congenital Malformations of the Skin'. In the current data it is applied to a case of 'Microscopic Peri-umbilical Lymphatic Malformation'⁴.

⁴ It is likely that this was a 'microcystic' rather than a 'microscopic' lesion.

This was apparently picked-up on ultrasound scan at 20 weeks gestation, (although an abnormality was recognized it is unlikely that an exact diagnosis was made). The pregnancy continued to the live birth of a female infant at 37 weeks gestation. No other abnormality was seen.

Figure 3.4: Point of Diagnosis of Primary Abnormality for Live-births, (n=218)



3.2. Stillbirth

The data records eight stillbirths with a defined abnormality during the study period. The mean gestation at delivery was 30.3 weeks. In all cases the primary abnormality was diagnosed on antenatal ultrasound scan prior to the loss. The mean gestation of diagnosis, (for the seven cases in which this data is available), was 17.6 weeks.

Q220	PULMONARY ATRESIA	Hypoplastic [®] Heart; VSD; Upper limb defect
Q318	LARYNGEAL ATRESIA	Male; Prenatal diagnosis
Q3799	CLEFT LIP & PALATE - COMPLEX	Situs inversus; AVSD; Atrial isomerism
Q6140	MULTICYSTIC DYSPLASTIC KIDNEY (L)	Coarctation of aorta; VSD;
Q643	URETHRAL OBSTRUCTION SEQUENCE	Male; Prenatal diagnosis
Q900	TRISOMY 21	Male; Prenatal diagnosis
Q900	TRISOMY 21	AVSD; Short rib syndrome
Q910	TRISOMY 18	AVSD

The case of complex cleft lip and palate had a number of associated cardiac abnormalities including AVSD, atrial isomerism, mitral and aortic valve malformations, and malformations of the great arteries against a background of situs inversus⁵. This case may have been better classified as a primarily cardiac abnormality. Likewise the case of pulmonary atresia was associated with hypoplastic right heart and a reduction defect of the upper limbs.

⁵ Situs inversus is an autosomal recessive condition with 2 sub-groups – dextrocardia and levocardia. An individual has levocardia if the heart is on the left (normal) side but all other organs are reversed. A further case where situs inversus was the primary diagnosis recorded as a fetal loss

3.3. Spontaneous Fetal Loss

There were eighteen fetal losses recorded in the 2013-2014 data. Previous reviews have documented a high proportion of chromosomal abnormalities in this group and once again 67% of losses were associated with fetal aneuploidy. The mean gestation at time of loss was 13.5 weeks, (range 9 – 20 weeks)

Q2115	SINGLE ATRIUM	15 weeks; Cong. malformation pulm. artery
Q2510	PRE-DUCTAL COARCTATION AORTA	20 weeks; Malposition of heart
Q649	LOWER URINARY TRACT OBSTRUCTION	14 weeks
Q792	EXOMPHALOS	15 weeks; Talipes; Mosaic monosomy X
Q8724	SIRENOMELIA	15 weeks
Q893	SITUS INVERSUS	19 week; Malrotation of gut
Q910	TRISOMY 18	16 weeks; Cystic hygroma
Q910	TRISOMY 18	11 weeks
Q914	TRISOMY 13	13 weeks; Cystic hygroma
Q927	TETRAPLOIDY	11 weeks
Q960	TURNERS SYNDROME	19 weeks
Q960	TURNER (MONOSOMY X) SYNDROME	12 weeks
Q960	TURNER SYNDROME	15 weeks; Cystic hygroma
Q969	TURNER SYNDROME	11 weeks
Q998	TRISOMY 15	8 weeks
Q998	TRISOMY 16	11 weeks
Q998	TRISOMY 15	9 weeks; Klinefelter XXY
Q998	TRISOMY 15	9 weeks

The ICD10 coding of Q872 covers congenital malformation syndromes predominantly involving limbs and includes sirenomelia and VATER/VACTERL association.

3.4. Termination of Pregnancy

A total of eighty-one cases were terminated following prenatal diagnosis, (Figure 3.5). The mean gestation at termination was 16.3 weeks, (range 11 to 23 weeks).

Chromosomal abnormality was the commonest indication for termination, (n=44), followed by neural tube defects and other cranial and spinal abnormalities, (n=17). Cranial and Spinal indications for termination included seven cases of anencephaly, seven cases of spina bifida and single cases of exencephaly, alobar holoprosencephaly and encephalocele, (large posterior). Termination of pregnancy was also undertaken for cases of transposition of the great vessels, hypoplastic right heart and hypoplastic left heart.

Fanconi anaemia is a rare, inherited blood disorder that leads to bone marrow failure but over 50% of individuals with Fanconi anaemia also have physical abnormalities. Recognized features of Fanconi anaemia include malformed thumbs or forearms and other skeletal problems including short stature; malformed or absent kidneys and other defects of the urinary tract; gastrointestinal abnormalities; heart defects; eye abnormalities such as small or abnormally shaped eyes; and malformed ears and hearing loss. Eighty to ninety percent of cases of Fanconi anaemia are due to mutations in one of three genes, *FANCA*, *FANCC*, and *FANCG*. Fanconi anaemia is most often inherited in an autosomal recessive pattern but rarely, this condition is inherited in an X-linked recessive pattern. The case described was a termination of pregnancy at 20 weeks gestation following prenatal diagnosis. Reduction defects of the upper limbs and deformity of the skull were the predominant features on scan. Fetal gender is not recorded.

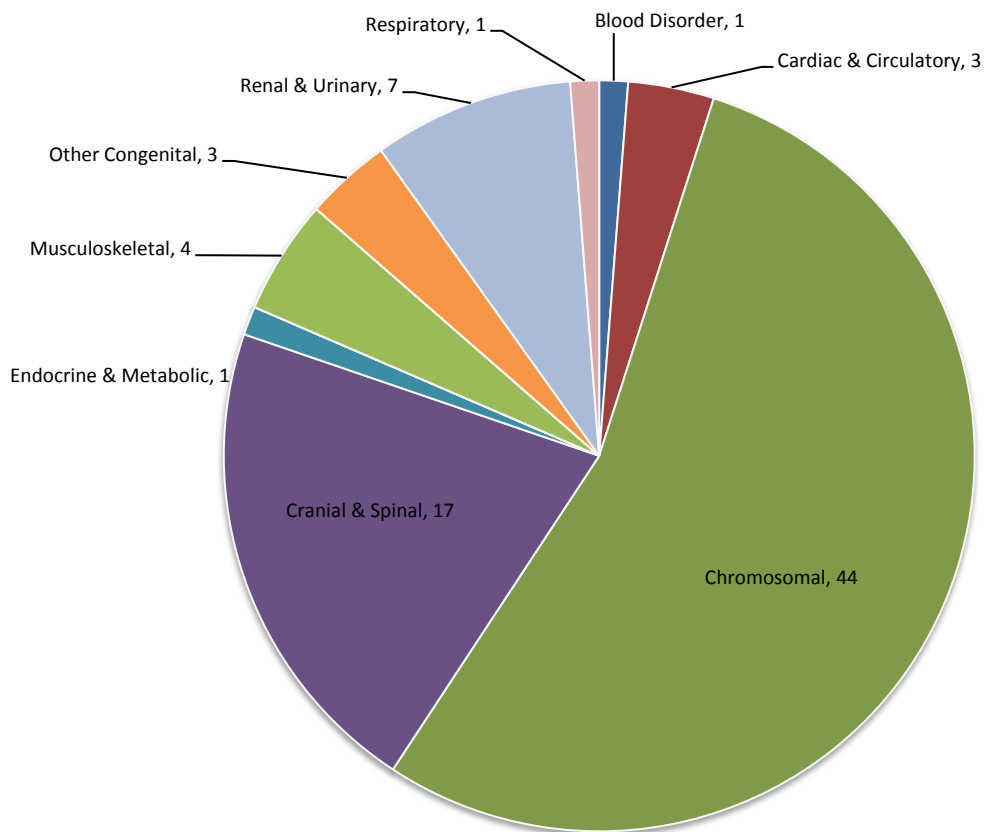
A fetus with methylmalonic aciduria was terminated at nineteen weeks following prenatal diagnosis.

Termination of pregnancy was performed at 21 weeks gestation following the prenatal diagnosis of laryngeal stenosis. There were a number of associated abnormalities.

Cases classified as having 'Other Congenital Abnormality' included amniotic band sequence, Fryn's syndrome and Pentalogy of Cantrell.

A female fetus with a primary diagnosis of 'hyperextended legs' was terminated at 21 weeks gestation after routine anomaly scan had demonstrated hand deformities, talipes and an unspecified malformation of the neck. Termination was also performed for cases of arthrogyrosis and flexion contractures of all limbs.

Figure 3.5: Diagnostic indication for Termination of Pregnancy (Simplified Classification), (n=81)

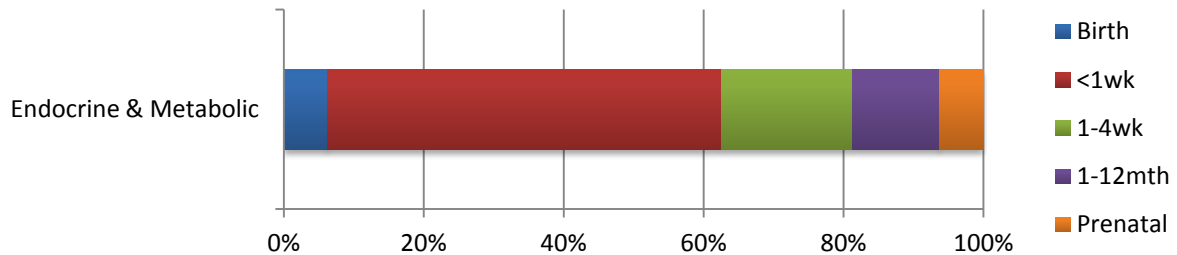


4. Review by Defined Abnormality

4.1. Endocrine & Metabolic Disorders

These disorders are typically diagnosed as a consequence of Newborn Bloodspot screening within the first few weeks of life, (Figure 4.1).

Figure 4.1: Point of Diagnosis: Endocrine & Metabolic Disorders, (n=16).



4.1.1. Congenital Hypothyroidism, (E0310; E0312; E039)

Congenital hypothyroidism can be the result of a missing or 'misplaced' thyroid gland, hereditary, maternal iodine deficiency and maternal thyroid conditions and medication. Four cases of congenital hypothyroidism are described. All were live born female infants with no associated abnormalities.

E0312	CONGENITAL HYPOTHYROIDISM - ECTOPIC THYROID TISSUE
E0312	CONGENITAL HYPOTHYROIDISM - ECTOPIC THYROID
E039	CONGENITAL HYPOTHYROIDISM
E039	CONGENITAL HYPOTHYROIDISM

4.1.2. Congenital Hyper-insulinism, (E161, E169)

Congenital hyperinsulinism, (CHI), describes a variety of disorders in which hypoglycaemia results as a consequence of excessive insulin secretion. This may be manifest in a variety of ways. For example, irritability, lethargy, cyanosis, hypothermia, and seizures are all associated with neonatal hypoglycaemia. Transient hyperinsulinaemia can also be seen in infants of diabetic mothers or as a consequence of IUGR.

There were two cases of congenital hyperinsulinism recorded. In both cases the diagnosis was made between 1 and 4 weeks of life.

E161	CONGENITAL HYPERINSULINISM	Male; Live-birth at 39 weeks
E169	CONGENITAL HYPERINSULINISM	Female; Live-birth at 39 weeks; PDA

In the past a number of different terms have been used to describe this condition including beta cell dysregulation syndrome, islet cell adenomatosis, and nesidoblastosis. The ICD10 classification is still a little vague. The ICD10 code 'E161' simply means 'Other hypoglycaemia' and includes functional non-hyperinsulinaemic hypoglycaemia as well as hyperinsulinaemia and post hypoglycaemic coma encephalopathy. Likewise 'E169' encompasses any disorder of pancreatic cell secretion such as islet cell hyperplasia.

4.1.3. In-born Errors of Metabolism

In-born errors of metabolism, (IEM), are a group of disorders in which a single gene defect causes a clinically significant block in a metabolic pathway leading either to an accumulation of the substrate or a deficiency of the product. They are individually rare but collectively common.

4.1.4. Disorders of Aromatic Amino-Acid Metabolism, (E70)

Phenylketonuria, (PKU), (E700)

Phenylketonuria is an autosomal recessive metabolic disorder of the hepatic enzyme phenylalanine hydroxylase. A single case of phenylketonuria was seen in a female infant delivered at term.

E700	PKU	Live-birth; Diagnosis in 1 st week
------	-----	---

The diagnosis was made on blood spot testing in the first week of life.

Albinism, (E703)

Two cases of albinism are described. They share the same ICD10 classification but differ in regard to clinical features, genetic mutation and inheritance pattern.

E703	WAARDENBURG SYNDROME	Live-birth; Diagnosed at birth; Hearing loss
E703	ALBINISM-OCULOCUTANEOUS	Live-birth; Diagnosed after 1 month

Oculo-cutaneous albinism is a group of conditions that affect pigmentation. Affected individuals typically have very fair skin and white or light-coloured hair. Oculo-cutaneous albinism also reduces pigmentation of the iris and retina. Hence visual problems such as reduced acuity, nystagmus and photophobia are common. There are four types of oculo-cutaneous albinism designated as type 1 (OCA1) through type 4 (OCA4). The four types of oculo-cutaneous albinism are most accurately distinguished by their genetic cause because the clinical features often overlap. All are inherited in an autosomal recessive pattern.

Similarly Waardenburg syndrome is associated with disorder of skin and hair pigmentation but it is usually inherited in an autosomal dominant pattern. The four known types of Waardenburg syndrome are distinguished by their physical characteristics and sometimes by their genetic cause. It is likely that this was a case of type II Waardenburg syndrome on the basis of the associated hearing loss. The hearing loss can be profound. Although type 1 is remarkably similar there is often hypertelorism. Type III is associated with limb defects and hearing loss. Type IV has signs and symptoms of Hirschsprung's disease.

4.1.5. Disorders of Branched Chain Amino-Acid and Fatty Acid Metabolism, (E71)

Methylmalonic aciduria with homocystinuria, (E7113)

The organic acidurias, such as methylmalonic aciduria, are characterized by marked metabolic acidosis with ketosis often with elevated lactate and hyperammonaemia.

The central error is a disorder of enzyme methylmalonyl-CoA-mutase which converts methylmalonyl CoA to succinyl CoA. Vitamin B12 is a co-factor in this process. It is inherited as an autosomal recessive disorder. Cases are typically diagnosed in the the early neonatal period with vomiting, neutropenia, thrombocytopenia, progressive encephalopathy and hyperammonaemia.

Homocystinuria describes an increased excretion of the thio-amino acid homocysteine in the urine. The source of this increase may be one of many metabolic factors and not just a failure of the enzyme cystathione beta synthase.

E7113 METHYLMALONIC ACIDURIA Prenatal diagnosis; Termination

Methylmalonic acid, (MMA), increases in the amniotic fluid of affected fetus and prenatal diagnosis can be achieved⁶.

Medium-chain Acyl-CoA Dehydrogenase Deficiency, (MCAD), (E713)

Fatty acid oxidation defects such as MCAD are a distinct type of organic acid disorder characterized by hypoketotic hypoglycaemia, hyperammonaemia and cardiomyopathy.

MCAD is among the most common of all IEM's and is also believed to account for up to 5% of all SIDS cases. It is caused by a mutation in the *ACADM* gene on chromosome 1. As a consequence of this mutation gluconeogenesis is effectively inhibited and the body is unable to metabolize fats during periods of fasting or metabolic stress. The clinical result is severe hypoglycaemia and hypoketonuria with elevated acylcarnitines such as octanoylcarnitine in the blood.

E713 MCAD DEFICIENCY Live-birth; Male infant; Diagnosed after 1 month

MCAD deficiency is identified by quantitative detection of acylcarnitines from dried blood spots.

4.1.6. Other Disorders of Carbohydrate Metabolism

'Classic' Galactosaemia – GALT deficiency, (E742)

This is a rare disorder of carbohydrate metabolism which is inherited in an autosomal recessive manner. It results from a deficiency of the enzyme galactose-1-phosphate uridyl transferase. Affected infants are normal at birth but develop jaundice, vomiting and diarrhoea shortly after commencement of milk feeds. If the disorder remains unrecognized liver disease, cataracts and mental retardation will result. Luckily most infants are diagnosed on new born screening.

E742 GALACTOSAEMIA- GALT DEFICIENCY Live-birth; Male infant; Diagnosed after 1 week

4.1.7. Cystic Fibrosis, (E840; E841; E849)

Approximately 1:2,500 babies born in the UK have cystic fibrosis. It is inherited as an autosomal recessive condition and affects the lungs, pancreas, liver and intestine. It is caused by any one of many different mutations in the gene for the protein cystic fibrosis transmembrane conductance regulator, (CFTR). The most common mutation, $\Delta F508$, is a deletion of three nucleotides that result in the loss of the amino acid phenylalanine at the 508th position on the protein. This mutation causes 70% of cases of cystic fibrosis world-wide.

There were four cases of cystic fibrosis diagnosed in 2013-2014, all were live births.

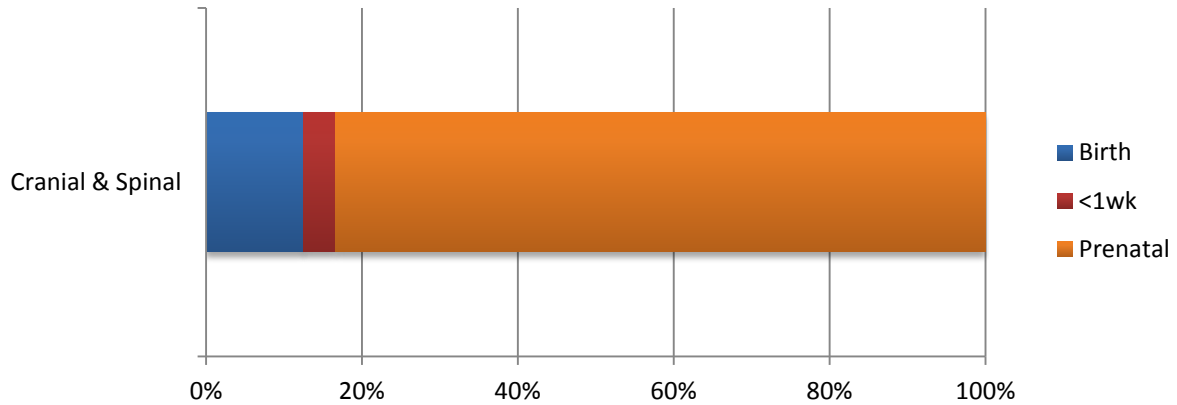
E840	CYSTIC FIBROSIS	Male; Lymphangioma; Diagnosed < 1 week
E840	CYSTIC FIBROSIS	Female; Talipes equino-varus; Diagnosed 1 – 4 weeks
E840	CYSTIC FIBROSIS	Male; Diagnosed < 1 week
E840	CYSTIC FIBROSIS	Female; Diagnosed < 1 week

⁶ Inove Y & Ohse M. Anal. Bioanal.Chem 2011:400(7); 1953-8

4.2. Cranial & Spinal Abnormalities

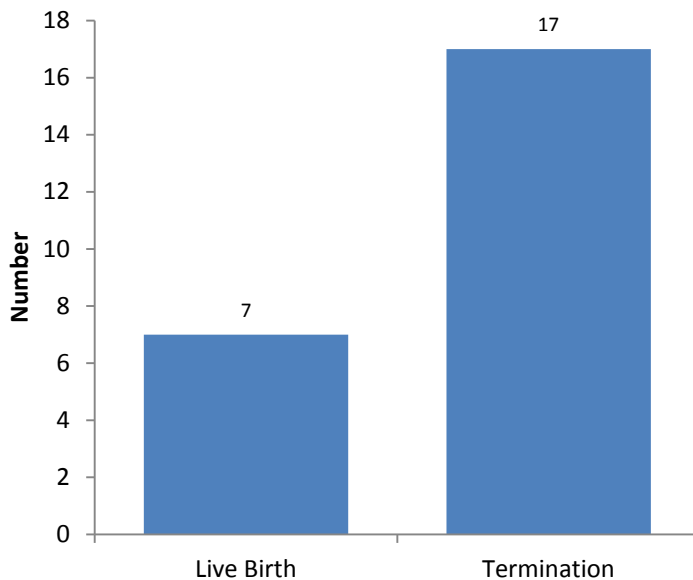
A total of 45 abnormalities of the central nervous system were recorded with 24 in the primary diagnostic position, (53%). Nearly eighty-four percent, (n=20), of the primary abnormalities are diagnosed on prenatal ultrasound scan assessment, (Figure 4.2).

Figure 4.2: Point of Diagnosis of Primary Cranial & Spinal Abnormality



The majority of pregnancies in which a primary diagnosis of cranial spinal abnormality was made ended in termination following prenatal diagnosis, (n=17, 70.8%), (Figure 4.3)

Figure 4.3: Outcome of Pregnancy with Primary Cranial & Spinal Abnormality

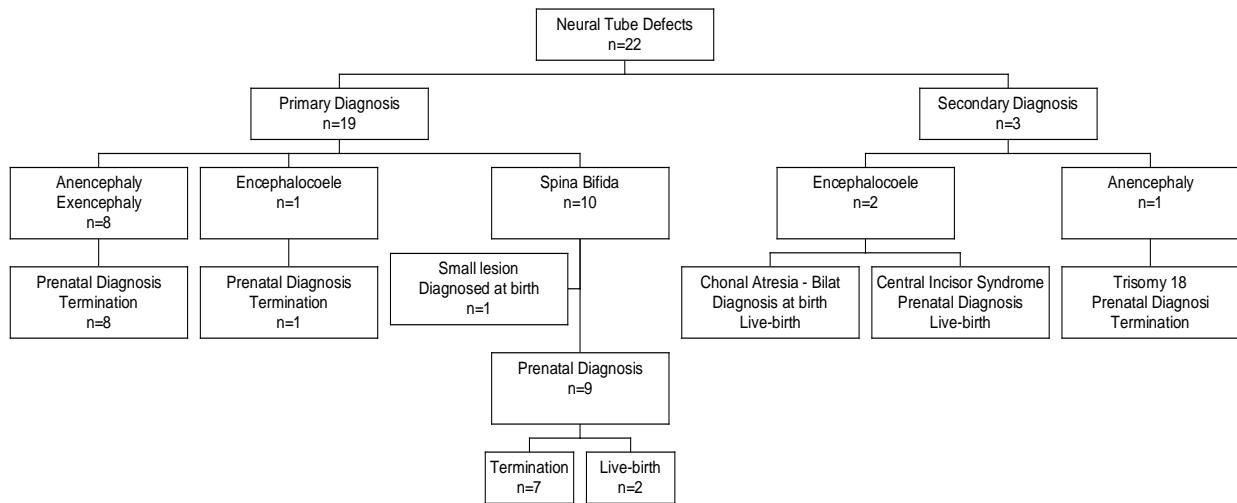


4.2.1. Neural Tube Defect, (NTD)

Neural Tube Defects are malformations of the brain and spinal cord. The clinical spectrum includes anencephaly, encephalocele, craniorachischsis, hydranencephaly, iniencephaly⁷, spina bifida cystica and spina bifida occulta. Twenty-two NTD's were defined in the 2013-2014 data, (Figure 4.4).

⁷ Iniencephaly is a rare malformation characterized by the triad of occipital bone defect, cervical dysraphism and fixed retroflexion of the fetal head.

Figure 4.4: Overview of Neural Tube Defects



Anencephaly, Acrania & Exencephaly, (Q000)

Anencephaly is defined as absence of the superior vault and cerebrum. It is the most common and severe anomaly of the central nervous system. The most striking feature at ultrasound is the presence of large bulging eyes marking the superior boundary of the fetus. Abrupt spasmodic body movements are not uncommon. The prognosis is grave and the severity of the condition justifies termination of the pregnancy. There were 9 cases of anencephaly/exencephaly. The majority were listed in the primary position and were all evident on prenatal scan.

Q000	ANENCEPHALY	Prenatal diagnosis; Termination
Q000	ANENCEPHALY	Prenatal diagnosis; Termination
Q000	ANENCEPHALY	Prenatal diagnosis; Termination
Q000	ANENCEPHALY	Prenatal diagnosis; Termination
Q000	ANENCEPHALY	Prenatal diagnosis; Termination
Q000	ANENCEPHALY	Prenatal diagnosis; Termination
Q000	ANENCEPHALY	Prenatal diagnosis; Termination
Q000	EXENCEPHALY	Prenatal diagnosis; Termination

The remaining case was seen in association with Trisomy 18

Q910	TRISOMY 18	Prenatal diagnosis; Termination at 9 weeks
------	------------	--

Encephalocele, (Q010, Q012, Q019)

A cephalocele is a defect in the bony skull through which meninges and brain substance may protrude. It is a result of a defect of neural tube closure during the sixth week of gestation. The location of the defect is mid-occipital in 75% of cases, fronto-ethmoidal in 13% and parietal in 12%. The bony defect is usually small in relation to the hernial sac. Differentiation is required from cystic hygroma, teratoma and amniotic band syndrome. Cephaloceles may occur in isolation or as a feature of various syndromes, (e.g. Meckel-Gruber).

One case of encephalocele was diagnosed on prenatal scan and listed in the primary diagnostic position. This was a female fetus with no associated abnormalities.

Q018	ENCEPHALOCELE - LARGE POSTERIOR	Prenatal diagnosis; Termination at 20 weeks
------	---------------------------------	---

Two further cases of encephalocele are described. A number of similarities are noted between these two cases despite the markedly different ICD10 classification.

Q300	CHOANAL ATRESIA - BILAT	Live-birth
Q878	SOLITARY MEDIAN MAXILLARY CENTRAL INCISOR SYNDROME	Live-birth

Frontal encephalocele was associated with bilateral chonal atresia, coloboma, cleft soft palate, plagiocephaly and pre-auricular cyst in a female infant delivered at term. There had been no suspicion of abnormality prior to delivery.

The unusual case of Solitary Median Maxillary Central Incisor syndrome in a male infant delivered at 36 weeks gestation is discussed later, (Part 4.5.5, Page 43).

Spina Bifida, (Q0511, Q0521, Q0531, Q055, Q0572, Q0582, Q059)

Spina bifida is a combined defect involving the spinal canal and its contents and is characterized by partial or complete absence of the vertebral arches. Spina bifida results from a primary failure of closure of the posterior vertebral arches involving one of more spinal segments. Posterior defects of neural tube closure are among the most common fetal abnormalities. Studies have shown that NTD's are ultimately based on the inadequate expression of certain pattern control genes. This may be caused by gene deletion, exogenous teratogenic agents, (e.g. valproic acid), or vitamin deficiency.

A total of ten cases of spina bifida are listed.

Q052	LUMBAR MELOMENINGOCELE (LARGE)	
Q052	L/S MYELOMENINGOCELE	
Q052	L/S SPINA BIFIDA	Arnold-Chiari Malformation
Q0521	L/S MYELOMENINGOCELE (OPEN) WITH HYDROCEPHALUS	Arnold-Chiari Malformation
Q053	SACRAL MYELOMENINGOCELE	Arnold-Chiari Malformation
Q0531	SACRAL MYELOMENINGOCELE	Arnold-Chiari Malformation
Q0572	L/S MYELOMENINGOCELE (CLOSED)	Arnold-Chiari Malformation
Q059	L/S SPINA BIFIDA	
Q059	L/S SPINA BIFIDA	
Q059	MYELOMENINGOCELE (SMALL), BASE OF SPINE	

The majority of diagnoses of spina bifida, (n=9, 90%), were made on prenatal ultrasound scan. Two pregnancies continued to live-birth at 37-39 weeks gestation following prenatal diagnosis. In seven cases termination of pregnancy was performed.

A small sacral myelomeningocele was diagnosed at time of delivery in a male infant at term. There had been no antenatal suspicion of abnormality.

4.2.2. Holoprosencephaly, (Q042)

This is a condition in which only a single large ventricle is seen or with a small skull containing no midline echo, disorganized cerebral ventricles and prominent cerebral peduncles. The disorder is associated with chromosomal defects, typically Trisomy 13.

Three forms are distinguished: alobar, semi-lobar and lobar holoprosencephaly. Both the alobar and semilobar forms are characterized by a single cystic cavity between the two hemispheres in the anterior part of the skull. Although holoprosencephaly is essentially a midline defect differentiation is required from pronounced hydrocephalus; in contrast to hydrocephalus ultrasound scan will show an absence of the midline echo and cavum septi pellucidi. Varying degrees of thalamic fusion are

seen depending on the form. Prognosis depends on the form. The alobar form is fatal but the semi-lobar and lobar forms are compatible with life at least until childhood. Significant mental retardation is to be expected.

Holoprosencephaly was recorded as a primary abnormality in one case. A secondary abnormality is coded as Q935. This is an ICD10 code for "Other deletion of part of chromosome".

Q042	HOLOPROSENCEPHALY - ALOBAR	Pre-natal diagnosis; Termination
------	----------------------------	----------------------------------

Holoprosencephaly was also seen as a secondary diagnosis in association with fetal aneuploidy.

Q910	TRISOMY 18	Pre-natal diagnosis; Termination
Q914	TRISOMY 13	Pre-natal diagnosis; Termination

Trisomy 18 was diagnosed following the finding of a cystic hygroma on booking scan at 11 weeks gestation. The case of Trisomy 13 was a later diagnosis made at time of the fetal anomaly scan. This case was associated with a number of other abnormalities including cleft lip and palate, abnormal nose, polydactyly and aplasia cutis congenita⁸.

4.2.3. Microcephaly, (Q02X)

Microcephaly is relatively rare with an incidence of 1:8500 births. The ultrasound diagnosis is based on the detection of a small skull. Craniometric parameters must be seen to be reduced on serial scans. Microcephaly is associated with many causes and usually results in severe mental retardation. Causes include CNS malformations, infections (CMV, rubella, and toxoplasmosis), chromosomal abnormalities, maternal PKU and certain teratogens, (including alcohol and cocaine).

There were three cases of microcephaly described in the data. In one case microcephaly is the primary diagnosis. This was a female infant delivered at term. The diagnosis of microcephaly was made between 1 and 4 weeks of life. There were no other associated features.

Q02X	MICROCEPHALY	Term delivery; Live-birth; Female;
------	--------------	------------------------------------

Two further cases of microcephaly are listed with the abnormality as a secondary feature.

Q899	UNDIAGNOSED GENETIC SYNDROME	Term delivery; Live-birth; Female
P358	CONGENITAL VARICELLA	Preterm delivery; Live-birth; Female

A female infant delivered at term was noted to have a number of abnormalities including microcephaly, abnormalities of the upper limbs, coloboma, malrotation of the gut, accessory kidney, ASD and stenosis of the lacrimal duct. The 'undiagnosis' was made between 1 and 12 months of life.

Overall the varicella zoster virus carries a relatively low risk to the fetus. However there is a well defined congenital varicella syndrome that is recognized to follow primary maternal infection. Congenital varicella syndrome is characterized by limb hypoplasia, cutaneous scars, cataracts, cerebral cortical atrophy and cerebellar hypoplasia⁹. The CNS manifestations result in microcephaly. The case listed above was a female infant delivered to an older mother prematurely at 30 weeks gestation. The diagnosis of congenital varicella syndrome was made after the first month of life.

⁸ Aplasia cutis is a condition with congenital absence of an area of skin. It is classically associated with Trisomy 13 but may also be seen following maternal exposure to methimazole and carbimazole.

⁹ Sauerbrei A & Wutzler P. The Congenital Varicella Syndrome. J. Perinatol. 2000; 20:548-54

Associated abnormalities included congenital cataracts and agenesis of the corpus callosum in addition to microcephaly, (see below).

4.2.4. Hydrocephalus, (Q030, Q039)

Surprisingly no cases of isolated hydrocephalus were described in the 2013-2014 data.

4.2.5. Other Cranial & Spinal Abnormalities

Agenesis of the Corpus Callosum, (Q0400)

The corpus callosum is a transverse fibre tract that connects the cerebral hemispheres at the base of the longitudinal fissure. It is not fully developed until 20 weeks gestation. The true frequency with which the corpus callosum fails to form is not known. There may well be asymptomatic individuals with partial or complete callosal agenesis. The ultrasound detection of a corpus callosum defect is difficult and requires a very detailed examination. Agenesis of the Corpus Callosum, (ACC), is commonly associated with other abnormalities and is listed as a secondary diagnosis in four cases.

Q758	POOR DEVELOPMENT OF MID-FACE	Termination
Q878	SOLITARY MEDIAN MAXILLARY CENTRAL INCISOR SYNDROME	Live-birth
Q935	DELETION 1p22	Female; Live-birth
P358	CONGENITAL VARICELLA	Female; Live-birth

The case listed as 'Poor Development of Mid-Face' was a termination of pregnancy at 17 weeks gestation following the prenatal diagnosis of multiple fetal abnormalities including micrognathia, reduction defects of the lower limbs, renal dysplasia as well as agenesis of the corpus callosum.

Arachnoid Cyst, (Q046)

Arachnoid cysts are rare intracranial cystic masses arising from the arachnoid membrane. They can be primary or secondary. Primary arachnoid cysts are a developmental anomaly whereas secondary cysts are acquired as a consequence of trauma, inflammation or intracerebral haemorrhage. The ultrasound appearances are of a fluid filled cyst that maybe midline or at an asymmetrical site. Generally the prognosis is good.

Q046	ARACHNOID CYST ® - LARGE	Prenatal diagnosis (late); Live-birth at term
------	--------------------------	---

The case listed above describes a male infant delivered at term. The presence of an arachnoid cyst was diagnosed on ultrasound just a few days prior to delivery.

NOTE: -

Malformations such as congenital spondylolisthesis and hemivertebral syndromes, (but not spina bifida occulta), are classified under 'Congenital disorders of the Musculoskeletal System'.

4.3. Cardiac & Circulatory

Disorders of the 'Heart & Circulatory System' are the second most common grouping of defined abnormalities, (n=102, 18.3%), and 35.3% of these abnormalities are in the primary diagnostic position, (36/102).

The most common cardiac abnormality was ventricular septal defect (VSD), (n=14), which was always recorded as a secondary diagnosis.

The severest forms of Congenital Heart Disease (CHD) should be identifiable on prenatal ultrasound scan by 24 weeks gestation. The classic 'four-chamber view' will diagnose the majority but certainly not all of these abnormalities. Additional views including visualization of both left and right outflow tracts are recommended to improve diagnostic ascertainment¹⁰.

As part of its review process EUROCAT defines a list of Severe Congenital Heart Defects, (Table 4.1). These, in essence, are those cardiac malformations that require surgical resolution.

Overall thirty-five cases displayed forty-one abnormalities that would fulfil the EUROCAT criteria for Severe Congenital Heart Disease. EUROCAT defined Severe Congenital Heart Defects are not always defined as the primary abnormality – they are secondary abnormalities in 50% of cases.

Table 4.1: EUROCAT Severe Congenital Heart Disease

Common arterial truncus (Q200)	No cases;
Transposition of Great arteries (Q203) ‡***	4; (1 primary, 3 secondary)
Single ventricle (Q204) *	1; (1 primary)
Atrioventricular septal defect (Q212)	7; (7 secondary)
Tetralogy of Fallot (Q213)	9; (8 primary, 1 secondary)
Tricuspid Atresia & Stenosis (Q224) ‡*	1; (1 secondary)
Ebstein's anomaly (Q225)	No cases;
Pulmonary valve atresia (Q220, Q221)*	5; (4 primary, 1 secondary)
Aortic valve atresia/stenosis (Q230)	1; (1 primary)
Hypoplastic left heart (Q234)	3; (3 primary)
Hypoplastic right heart (Q226) ‡**	3; (1 primary, 2 secondary)
Coarctation of aorta (Q251)	5; (3 primary, 2 secondary)
Total anomalous pulmonary venous return (Q262)	2; (2 primary)

* Four cases had two EUROCAT defined abnormalities.

‡ One case had three EUROCAT defined abnormalities, (hypoplastic right heart, tricuspid atresia and TGA).

Seventy-four percent of cases of EUROCAT defined severe congenital heart disease, (n=26) were live births, (Figure 4.5). Three cases were terminated following prenatal diagnosis of abnormality, two with a combination of transposition of the great vessels and hypoplastic right heart and the other with multiple abnormalities including hypoplastic left heart, aortic atresia, mitral stenosis and limb defects.

Overall twenty-one of these thirty-five EUROCAT defined severe cardiac cases had an abnormality diagnosed on prenatal scan giving a case detection rate of 60%, (Figure 4.6). The prenatal detection rate for the thirty-six cases classified as having a primary cardiac abnormality was 50%, (Figure 4.7).

¹⁰ NSC Recommendations.

Figure 4.5: Outcome of pregnancies associated with EUROCAT defined Severe Cardiac Abnormality, (n=35).

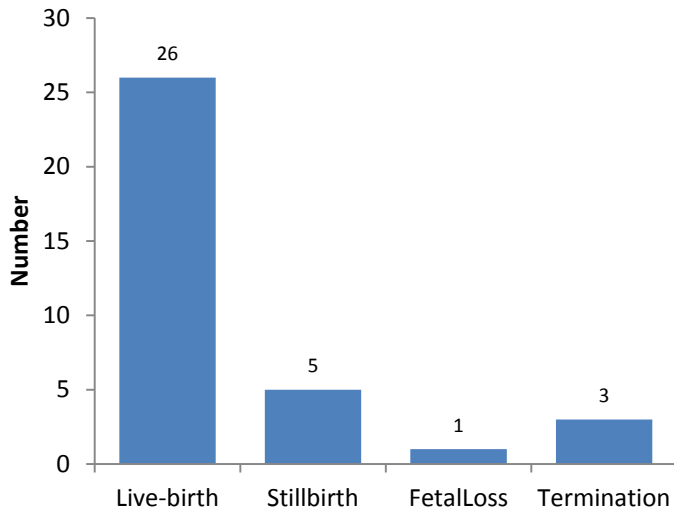


Figure 4.6: Point of Diagnosis of EUROCAT defined Severe Cardiac Abnormality, (n=35).

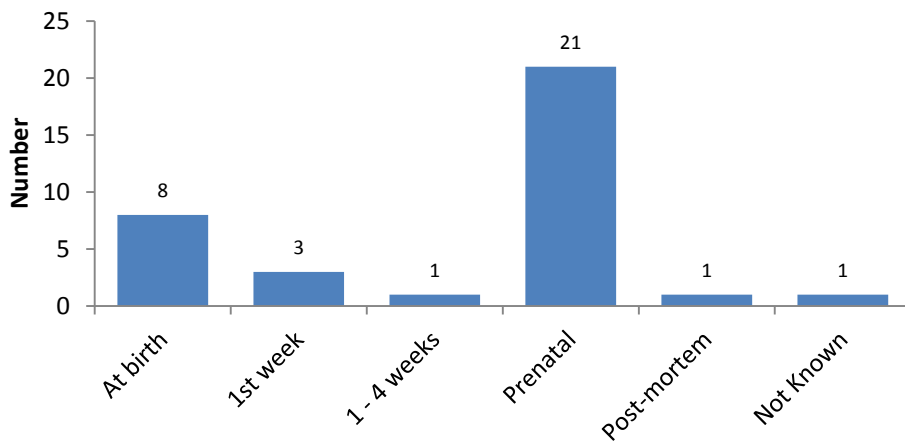
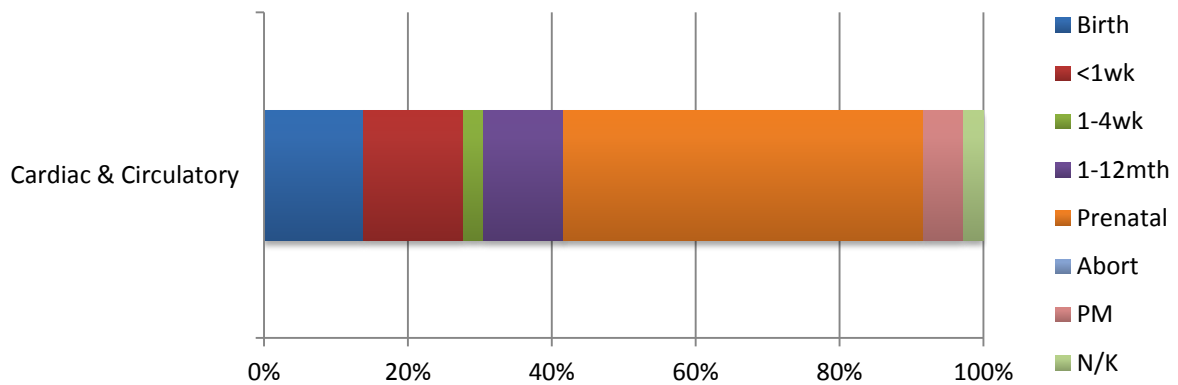


Figure 4.7: Point of diagnosis of ALL primary cardiac abnormalities, (n=36)



4.3.1. Transposition of the Great Vessels, (Q203)

In this anomaly there is ventriculo-arterial discordance with the aorta arising from the right ventricle and the pulmonary trunk from the left ventricle. However the connections between the atria and ventricles are other wise normal. It is a relatively frequent cardiac anomaly occurring in about 5-7% of all live births with a congenital heart defect.

This abnormality results from an abnormal division of the truncus arteriosus. In transposition the septum dividing the truncus has failed to rotate so that the aorta arises from the right ventricle and the pulmonary artery from the left. This leads to two independent circulations and would be incompatible with ex-utero life if it wasn't for the fact that there is nearly always a communication in the form of ASD, VSD or PDA. Extra-cardiac abnormalities are rare and prognosis is generally good.

Dextro-transposition of the great arteries cannot be detected prenatally with the standard four-chamber view: the four chamber view appears normal except in cases with an associated VSD. Its detection requires evaluation of the origin and course of the two great vessels. Defining the parallel course of both major vessels, along with their valves, in one plane is characteristic. In the less commonly used short-axis view the aorta is located anterior to the pulmonary trunk and the 'circle and sausage' sign is absent.

There were four cases where Transposition of the Great Vessels is recorded. In one case it is the primary abnormality whereas in the remaining three it is associated with other severe cardiac malformation.

Q203	TGV	Prenatal diagnosis; Termination
Q204	HYPOPLASTIC (L) HEART	Prenatal diagnosis; Live-birth
Q226	HYPOPLASTIC @ HEART	Prenatal diagnosis; Termination
Q8930	DEXTROCARDIA WITH SITUS INVERSUS	Prenatal diagnosis; Live-birth

Two additional cases were seen of discordant atrioventricular connection that don't fall into the strict EUROCAT definition of transposition of the great vessels, and are therefore not included in the diagnostic figures. They are included for completeness.

Q205	CONGENITALLY CORRECTED TGV	Live-birth; Male; Diagnosed at birth
Q205	CONGENITALLY CORRECTED TGA	Prenatal diagnosis; Live-birth; Female

In both cases there were additional cardiac abnormalities.

4.3.2. Atrioventricular Septal Defect, (AVSD), (Q212)

These defects involve a combination of low atrial and high ventricular septal defects and result from a failure of endocardial cushion development. An AVSD is usually associated with extracardiac anomalies particularly Trisomy 21. An AVSD is also often found in association with an abnormal cardiac position such as left or right sided isomerism. The prognosis depends on the associated extracardiac anomalies.

Q240	DEXTROCARDIA	Prenatal diagnosis; Live-birth
Q3799	CLEFT LIP & PALATE - COMPLEX	Prenatal diagnosis; Live-birth
Q900	TRISOMY 21	Live-birth; Diagnosis at birth
Q900	TRISOMY 21	Live-birth; Diagnosis at birth
Q900	TRISOMY 21	Prenatal diagnosis; Stillbirth
Q900	TRISOMY 21	Live-birth; Diagnosis at birth
Q910	TRISOMY 18	Prenatal diagnosis; Stillbirth

This diagnosis should be considered whenever a defect is noted in the portion of the atrial septum near the AV valves on a standard four-chamber view.

The prenatal detection rate of atrio-ventricular septal defect was only 57.1% in this series, (66% in 2012-2013).

4.3.3. Fallot's Tetralogy, (Q213)

Fallot's Tetralogy is a single error of development with four consequences. The septum dividing the truncus instead of joining up with the inter-ventricular septum deviates to the right. The right ventricular outflow is therefore restricted, (pulmonary stenosis or atresia), the aorta extends to the right of the septum, (over-riding aorta), and receives blood from both ventricles and there is a deficiency in the upper part of the membranous septum, (VSD). The right ventricle hypertrophies to pump blood through both a narrowed pulmonary orifice and the aorta.

Only two of the four abnormalities that characterize Fallot's Tetralogy, (the VSD and the over-riding aorta), can be definitively detected on prenatal scan. The pulmonary stenosis is a consequence of under perfusion of the valve and therefore 'evolves' during intrauterine and postnatal life. Right ventricular hypertrophy is secondary to the increased workload of the right ventricle and is generally diagnosed after delivery but a few severe cases are detected on scan in pregnancy.

Nine cases of Fallot's Tetralogy are listed in the 2013-2014 data. All were live-births at term. In the majority the abnormality is recorded in the primary position.

Q213	TETRALOGY OF FALLOT	Prenatal diagnosis
Q213	TETRALOGY OF FALLOT	Prenatal diagnosis
Q213	TETRALOGY OF FALLOT	Prenatal diagnosis; Cong. abnormality of pulmonary artery
Q213	TETRALOGY OF FALLOT	Prenatal diagnosis
Q213	TETRALOGY OF FALLOT	Prenatal diagnosis
Q213	TETRALOGY OF FALLOT	Diagnosed at birth
Q213	TETRALOGY OF FALLOT	Anal atresia with fistula; Diagnosed at birth
Q213	TETRALOGY OF FALLOT	Prenatal diagnosis

The severity is variable and, as mentioned, earlier 'mild' cases are likely to be missed by ultrasound. However, prenatal diagnosis was achieved in a six cases: a prenatal diagnosis rate of 75%. The two remaining cases were diagnosed at birth.

The anomaly is recorded as an associated diagnosis in one further case.

D821	DI GEORGE SYNDROME	Tetralogy of Fallot; Thyroglossal cyst; Hypospadias
------	--------------------	---

The point of diagnosis for this case is not recorded but this was also a live-birth at term. The ICD10 code 'Q935' or 'Other deletion of part of a chromosome', is also listed against this case. This is not surprising in that Di George syndrome is more appropriately considered as a 22q11.2 deletion sequence rather than a primary disorder of the haematological system!

4.3.4. Pulmonary Valve Atresia & Stenosis, (Q220, Q221)

Pulmonary valve atresia leads to hypoplasia of the right ventricle with pronounced myocardial hypertrophy and secondary dysplasia of the tricuspid valve. An atrial septal defect is often present as an associated cardiac anomaly. The standard four-chamber view may demonstrate hypoplasia, myocardial hyperplasia and hypokinesia of the right ventricle.

Pulmonary stenosis, on the other hand, refers to narrowing of the right ventricular outflow tract in the area of the pulmonary valve. The stenosis is classified by location as valvular, sub-valvular and supra-valvular. Extra-cardiac anomalies are uncommon and it is rarely associated with chromosomal abnormality.

A case where multiple abnormalities were detected on ultrasound scan at 11 weeks gestation was a stillbirth at 25 weeks. Abnormalities included hypoplastic right heart, VSD, reduction defects of the upper limbs and webbed fingers.

Q220	PULMONARY ATRESIA	Prenatal diagnosis; Stillbirth
Q221	PULMONARY VALVE STENOSIS	Live-birth; Diagnosed at birth
Q221	DYSPLASTIC THICKENED TRILEAFLET PULMONARY VALVE	Prenatal diagnosis; Live-birth
Q221	PULMONARY VALVE STENOSIS	Live-birth; Diagnosis in 1 st wk.
Q998	UNBAL TRANSLOC: 10q24 DUPLICATION & 4q13 DELETION	Live-birth; Diagnosed at birth.

4.3.5. Hypoplastic Left Heart Syndrome, (Q234)

This is a group of defects in which the left ventricle may be absent or extremely hypoplastic as a result of a combination of aortic atresia and mitral valve atresia or stenosis. Approximately 10% of cases are associated with a chromosomal abnormality, usually Trisomy 13, Trisomy 18 or Turner syndrome. Hypoplastic Left Heart syndrome is readily diagnosed on prenatal scan. In severe cases the four-chamber view is already abnormal in the second trimester. The lumen of the left ventricle may be extremely small or simply not visualized. The aorta is extremely hypoplastic and its origin and course are difficult to define. Compensatory dilatation of the right ventricle and pulmonary trunk may be present.

Incidence is typically quoted at 0.2/1000 live-births, (0.02%). Hypoplastic left heart accounts for 7-9% of all cases of congenital heart disease diagnosed during the first year of life.

Three cases of hypoplastic left heart syndrome, (Q234), were diagnosed in NHS GG&C during 2013-2014.

Q234	HYPOPLASTIC (L) HEART	Prenatal diagnosis; Live-birth
Q234	HYPOPLASTIC (L) HEART	Prenatal diagnosis; Multiple cardiac anomalies; Termination
Q234	HYPOPLASTIC (L) HEART	Prenatal diagnosis; Live-birth

There was a further case of what was essentially hypoplastic left heart syndrome that was labelled as 'Single Ventricle' under the ICD10 code of Q204. That case was also associated with TGA and pulmonary artery stenosis.

4.3.6. Coarctation of the Aorta, (Q251)

A simple coarctation of the aorta is difficult to diagnose on prenatal scan. Visualization of the aortic arch in longitudinal section is not a regular feature of prenatal ultrasound scan. There may be disproportion between the left and right ventricles and between the aortic arch and pulmonary trunk. However, this is not a reliable diagnostic feature as a slight discrepancy in size between left and right ventricle will be seen in a healthy third trimester fetus.

Coarctation of the aorta is accompanied by extra-cardiac anomalies in 25% of cases. Typical anomalies include those whose embryonic development coincides with the timing and location of

aortic arch development and include upper gastrointestinal tract anomalies such as oesophageal atresia and diaphragmatic defect.

A total of five cases of coarctation of the aorta were seen during 2013-2014. The prenatal detection rate for this EUROCAT defined Severe Congenital Heart Defect was 60%, (n=3).

Q251	COARCTATION AORTA	Prenatal diagnosis; VSD
Q251	COARCTATION AORTA	Isolated; Diagnosed between 1 – 4 weeks
Q2510	COARCT AORTA - PRE-DUCTAL	Fetal loss at 20 weeks
Q6140	MULTICYSTIC DYSPLASTIC KIDNEY (L)	Stillbirth; Multiple cardiac anomalies
Q8930	DEXTROCARDIA WITH SITUS INVERSUS	Live-birth; Multiple cardiac anomalies

4.3.5. Total Anomalous Pulmonary Venous Drainage, (TAPVD), (Q262)

Total (or partial) anomalous pulmonary venous return is present when all or some of the pulmonary veins drain into the right atrium or into the venae cavae that enter the right atrium.

Total Anomalous Pulmonary Venous Drainage (TAPVD) is difficult to diagnose on prenatal scan unless the drainage is grossly distorted. Possible suggestive signs include a left atrium that is somewhat smaller than the right atrium or the presence of a persistent left superior vena cava, (often best seen in the ‘three vessel view’ where it appears as a 4th vessel to the left of the pulmonary trunk). However, prognosis is generally good.

Q262	TAPVD	Live-birth; Diagnosis 1 – 4 weeks
Q262	TAPVC	Live-birth; Diagnosis at birth

A case of partial anomalous pulmonary venous connection, (Q263), was seen in association with mosaic trisomy for a partial ring 14 chromosome in a male infant delivered at 39 weeks gestation. The formal diagnosis was made between 1 and 4 weeks of life. A VSD was also present.

Q928	MOSAIC TRISOMY FOR A PARTIAL RING 14 CHROMOSOME
------	---

4.4. Congenital Malformations of the Respiratory System.

A total of eight respiratory tract abnormalities are classified in the primary diagnostic position.

4.4.1. Choanal Atresia, (Q300)

This abnormality results from a failure of recanalization of the nasal fossae during fetal development. Consequently the choana remain blocked by bony and/or membranous tissue. The blockage may be unilateral or bilateral. Any condition that causes significant depression of the nasal bridge or mid-face can be associated with choanal atresia. Neonates are obligate nose breathers and bilateral choanal atresia can be a serious issue.

Q300	CHOANAL ATRESIA (L)	Preterm at 26 weeks
Q300	CHOANAL ATRESIA - BILAT	Female: Term delivery
Q878	SOLITARY MEDIAN MAXILLARY CENTRAL INCISOR SYNDROME	Live-birth at 36 weeks

There were three cases of choanal atresia described, one in association with Solitary Medial Maxillary Central Incisor syndrome, (Part 4.5.5, Page 43). All were live-births with the diagnosis of choanal atresia being made shortly after birth in two cases. A female infant delivered prematurely at 26 weeks gestation had a unilateral (left-sided) choanal atresia which was diagnosed between 1 and 12 months of life.

The female infant with bilateral choanal atresia also demonstrated a number of additional malformations including frontal encephalocele, coloboma, cleft soft palate, plagiocephaly and a pre-auricular cyst. There had been no suggestion of abnormality prior to delivery, (Part 4.2.1, Page 30).

4.4.2. Laryngeal Atresia, (Q318)

Congenital atresia of the larynx is a rare abnormality of the upper airway. Prenatal diagnosis can be difficult but diagnosis has been made as early as 15 weeks¹¹. Increased lung echogenicity, a fluid filled trachea and ascites are the typical diagnostic features and inversion of the diaphragm may be present. Polyhydramnios may also be seen.

The two cases listed in the current data were diagnosed on prenatal scan at 19 weeks

Q318	LARYNGEAL STENOSIS	Multiple abnormalities
Q318	LARYNGEAL ATRESIA	Stillbirth at 34 weeks

Laryngeal atresia/stenosis can be associated with other structural and genetic abnormalities particularly renal agenesis and intestinal malformations. Termination of pregnancy was performed at 21 weeks gestation following the prenatal diagnosis of laryngeal stenosis and other malformations including malformation of the cardiac septa, renal dysplasia, polysyndactyly, lissencephaly and Meckel diverticulum.

4.4.3. Congenital Cystic Adenomatoid Malformation, (Q338, Q3380)

The respiratory system starts to develop at around 3 week's gestation. Aberrations in the developmental process may give rise to a group of structural malformations collectively referred to as broncho-pulmonary foregut malformations, (BPFM's). The three commonest are Sequestration, Congenital Cystic Adenomatoid Malformation and Congenital Lobar Emphysema.

¹¹ Chaemsaitong P et al. Case Rep. Radiol. 2012.

Congenital Cystic Adenomatoid Malformation, (Q338, Q3380).

Congenital cystic adenomatoid malformation (CCAM) is a rare unilateral hamartomatous dysplasia of the lung. Three pathological types are recognized: Type 1 with cysts >2cm diameter, Type II with cysts <1cm diameter and Type III a predominantly solid type with microcysts. The ultrasound features are consistent with the pathological changes. The affected lung is markedly enlarged in all three types and leads to a mediastinal shift to the opposite side and as a result normal lung tissues become compressed. The mediastinal displacement can also compromise venous return leading to fetal hydrops. Prognosis is dependent upon histological type, (in general Types II and III are associated with a poor prognosis), the development of hydrops, severity of pulmonary hypoplasia on the unaffected side, timing of diagnosis and early planned intervention.

There were two cases of congenital cystic adenomatoid malformation listed in the primary position.

Q3380	CCAM ® Middle Lobe	Pre-natal diagnosis; Live-birth
Q3380	CCAM (L)	Pre-natal diagnosis; Live-birth

A third case was seen in association with spina bifida.

4.4.4. Neuroenteric Cysts, Q341

Neuroenteric cysts represent a failure of complete separation of the notochord from the foregut during the 3rd week of embryogenesis. They are rare and usually located in the posterior mediastinum but can be intracranial. Neuroenteric cysts are frequently associated with vertebral anomalies including hemi-vertebrae. As a consequence of the significant lung hypoplasia symptoms of respiratory distress are usually evident at birth. Ultrasound shows a large cyst in the posterior mediastinum that typically displaces the heart and causes an irregularity of the thoracic spine.

Q341 FOREGUT DUPLICATION CYST POSTERIOR MEDIASTINUM

A single case is described in a male infant delivered at 36 weeks gestation following prenatal diagnosis. There was an associated malformation of the spine.

4.5. Face & Neck

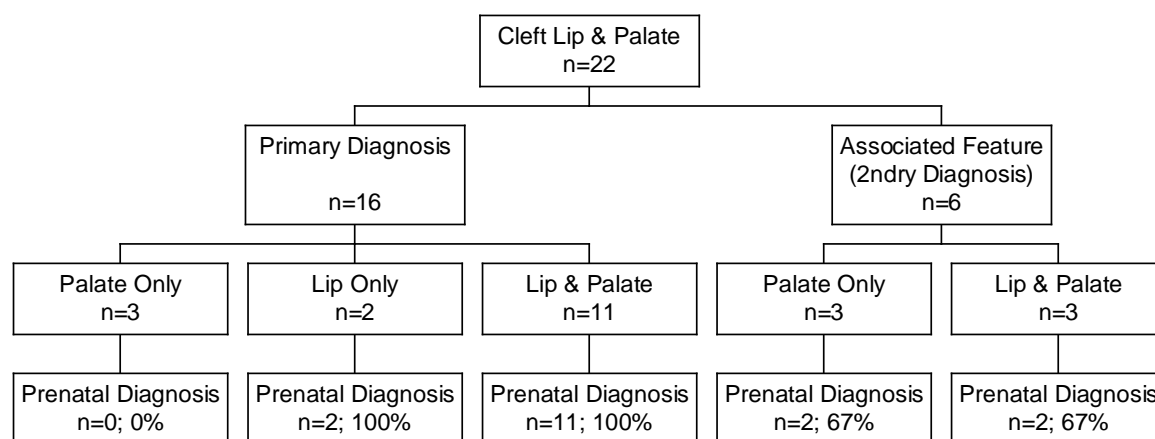
Congenital malformations of the head and neck are a wide and heterogeneous group that range in importance and severity from purely cosmetic defects to lethal anomalies. They can be isolated or occur as a component of a sequence, syndrome or chromosomal disorder.

4.5.1. Cleft Lip & Palate, (Q 352, Q3539, Q3599, Q3690, Q3699, Q378, Q3799)

Cleft lip and palate are among the more common congenital malformations. Clefts are mainly isolated lesions but are also found in association with various syndromes and chromosomal abnormalities, particularly Trisomy 13 and 18. Cleft lip and palate can be diagnosed on prenatal ultrasound scan in a coronal or sagittal scan through the face or in a transverse scan at the level of the maxilla. Large clefts are fairly conspicuous but a small cleft may be easily overlooked: with a small lip cleft the coronal scan shows only a narrow defect in the upper lip.

A total of 22 cases are recorded with cleft lip, cleft palate or both, (Figure 4.8).

Figure 4.8: Overview of Cleft Lip & Palate



Sixteen cases of cleft lip were listed overall, (either isolated or associated with cleft palate or other abnormality). Prenatal diagnosis was achieved in 15 cases of these cases.

Cleft palate, (with or without cleft lip), was seen in 20 cases. Of these, cleft palate was recorded as a secondary diagnosis in six cases.

Q688	FLEXION CONTRACTURES ALL LIMBS	Palate only
Q8708	PIERRE ROBIN SEQUENCE	Palate only
Q998	UNBAL TRANSLOC: 10q24 DUPLICATION & 4q13 DELETION	Cleft lip & palate
Q300	CHOANAL ATRESIA - BILAT	Palate only
Q914	TRISOMY 13	Cleft lip & palate
Q914	TRISOMY 13	Cleft lip & palate

Where prenatal diagnosis of cleft palate was achieved it was typically in association with another anomaly such as cleft lip or a chromosomal syndrome. None of the 3 cases of isolated cleft palate were diagnosed on antenatal scan they were all diagnosed at birth.

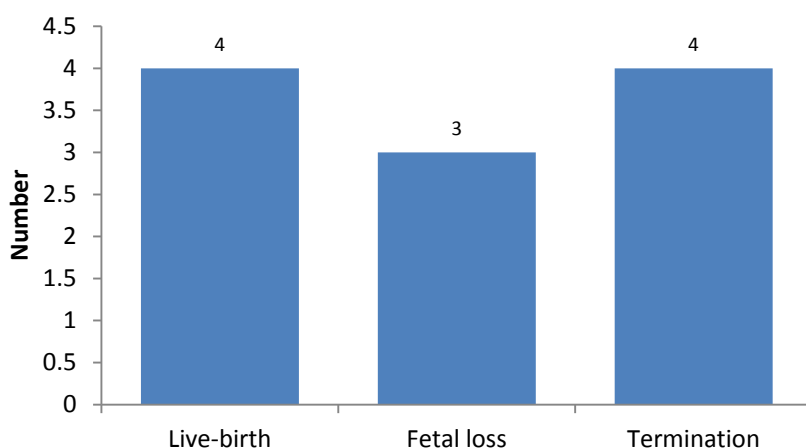
4.5.2. Congenital Cavernous Lymphangioma, 'Cystic Hygroma', (D181, D1810).

The presence of a congenital cavernous lymphangioma is recorded for 11 cases. Typically the data only records the presence of a congenital lymphangioma - it does not record location. The presumption is made from the data provided that a 'cystic hygroma' is seen at the neck but lymphangioma may present at other locations such as the limbs.

Lymphangioma was a primary isolated finding in two cases and a secondary abnormality in the remaining nine. Cystic hygroma was associated with chromosomal abnormality in eight cases, (72.7%). The majority of cases, (n=10, 90.9%), were identified prenatally. The remaining case, an 'extensive lymphangioma of the left neck' was diagnosed at preterm delivery of a live male infant.

Four cases were terminated following prenatal diagnosis, all in association with other abnormality. There were four live births and three fetal losses. The fetal losses were all associated with fetal aneuploidy, (Figure 4.9).

Figure 4.9: Outcome of pregnancies associated with cystic hygroma, (n=11)



4.5.3. Pierre-Robin Sequence, (Q870)

There was one case recorded of Pierre Robin Sequence, (severe micrognathia with a secondary cleft palate).

Q8708 PIERRE ROBIN SEQUENCE Prenatal diagnosis; Female; Live-birth at term

4.5.4. Congenital Cataracts, (Q120)

Approximately one third of congenital cataracts are a component of a more extensive syndrome or disease. However the origin a good 30% are unexplained. Metabolic disease tends to be associated with bilateral cataracts. Typical associations include Alports syndrome, Marfan syndrome, Down syndrome, Myotonic dystrophy, Galactosaemia, Trisomy 13 and congenital infections such as Rubella, Toxoplasmosis, CMV and Herpes Simplex.

There were three cases of bilateral cataracts with the abnormality recorded in the primary position on two occasions.

Q120 CONGENITAL CATARACT - BILAT No associated abnormality
 Q120 CONGENITAL CATARACT - BILAT Hearing loss; Congenital deformity of skull

Cataracts were also seen in association with Congenital Varicella syndrome, (Part 4.2.3, Page 31).

P358 CONGENITAL VARICELLA Pre-term delivery at 30 weeks

4.5.5. Other Face & Neck

Solitary Median Maxillary Central Incisor (SMMCI) Syndrome, (Q878)

This is a complex disorder consisting of multiple, mainly midline, defects of development resulting from unknown factors operating in utero at 25th to 38th day post conception¹². Routine mid-trimester prenatal ultrasound should detect a small head and abnormalities in position of the eyes and nose.

Q878 Solitary Median Maxillary Central Incisor Prenatal diagnosis; Live-birth at 36 weeks

A single case is described in the current data. Associated features included microphthalmos, encephalocele, lissencephaly, chonal atresia, agenesis of the corpus callosum and hypoplasia of the spinal cord.

Goldenhar Syndrome, (Q8704)

The ICD10 code Q870 refers to congenital malformation syndromes that predominantly affect facial appearance. It is a broad category that includes cyclopa, acrocephalopolysyndactyly, 'whistling face' and Goldenhar syndrome.

Goldenhar syndrome is also known as oculo-auriculo-vertebral syndrome and presents as incomplete development of the ear, nose, soft palate, lips and mandible. Goldenhar syndrome is believed to arise as a consequence of anomalous development of the 1st and 2nd branchial arches late in the first trimester.

Q8704 GOLDENHAR SYNDROME Live-birth; Male; Diagnosed at birth

A single case is seen in a male infant delivered at term. Associated features included congenital malformation of the ears, accessory auricle, accessory periauricular skin tags and hypospadias.

Moebius Syndrome, (Q8706)

This is another congenital malformation syndrome predominantly affecting the face. A single case was recorded in a male twin, (Part 1.5, Page 12).

¹² Hall RK. Orphanet. J. Rare. Dis. 2006: 1; 12. The name originally given was 'Solitary median maxillary central incisor, short stature, chonal atresia, mid-nasal stenosis syndrome' and was also known as 'mono-superoincisivodontic dwarfism'. The use of the single incisor tooth in the name emphasises the unique form and position of this tooth.

4.6. Gastrointestinal Abnormalities

The gastrointestinal tract is formed from anatomically and functionally distinct regions that may be subject to a variety of errors of embryological development. Patterns of malformation include abnormal lumenization, (stenosis and atresia), duplications, abnormal rotation and fixation and abdominal wall defects.

4.6.1. Oesophageal Atresia, (Q391)

Oesophageal atresia is an anomalous closure of the oesophagus that may or may not be associated with tracheo-oesophageal fistula. It arises from an error in the differentiation of the foregut into the oesophagus, trachea and lung at around 4-6 weeks gestation. A low tracheo-oesophageal fistula is present in around 90% of cases. Diagnosis is difficult with prenatal ultrasound but polyhydramnios and absence of the fetal stomach are helpful signs. However the presence of a fluid-filled gastric bubble does not exclude the abnormality if a low fistula is present. The reported ultrasound detection rate of oesophageal atresia is ranges from 12 to 42%.

One case is described with the abnormality in the primary position. The diagnosis was made at birth. Associated abnormalities included horseshoe kidney and VSD.

Q391 OESOPHAGEAL ATRESIA WITH TRACHEO-OESOPHAGEAL FISTULA

A further case is seen as part of the VACTERL association, a non-random relationship of birth defects that affects multiple organ systems¹³.

Q8726 VACTERL ASSOCIATION Female; Live-birth at term

4.6.2. Imperforate Anus, Anal Stenosis & Anorectal Atresia, (Q4200, Q421, Q4290)

These abnormalities are associated with a variety of perineal appearances including complete absence of the anus or anterior stenosis and anal fistula. They are often seen in association with abnormalities of the renal tract.

Q4200	IMPERFORATE ANUS/RECTO-PROSTATIC URETHRAL FISTULA	Post. urethral valves
Q421	IMPERFORATE ANUS	Horseshoe kidney
Q4290	COLONIC ATRESIA	

Imperforate anus is recorded as a secondary diagnosis in five cases.

Q600	ABSENT KIDNEY (L)	Prenatal diagnosis; Live-birth
Q606	POTTER'S SEQUENCE	Prenatal diagnosis; Termination
Q688	FLEXION CONTRACTURES ALL LIMBS	Prenatal diagnosis; Termination
Q900	TRISOMY 21	Prenatal diagnosis; Live-birth
Q213	TETRALOGY OF FALLOT	Live-birth; Diagnosis at birth

Prenatal sonographic diagnosis has been achieved following the identification of abnormal large bowel dilatation. Tables are available of normal lumen diameters across gestation. It is probable that any prenatal diagnosis achieved and listed above was of the primary abnormality rather than imperforate anus/anorectal atresia.

¹³ The term VACTERL is an acronym where V=vertebral abnormality; A=anal atresia; C=cardiac defects; T=tracheal anomalies including tracheo-oesophageal fistula; E=oesophageal atresia; R=renal and /or radial abnormality and L= other limb abnormalities.

4.6.3. Malrotation of Bowel, (Q433)

In ICD10 this is technically 'Congenital Malformations of Intestinal fixation' and includes a variety of conditions of small and large bowel.

Q433 MALROTATION Live birth; Diagnosed in 1st week

Malrotation of the gut is also documented as a secondary diagnosis in a further seven cases

Q601	RENAL AGENESIS - BILAT	Termination
Q878	FRYNS SYNDROME	Termination
Q893	SITUS INVERSUS	Fetal loss
Q899	UNDIAGNOSED GENETIC SYNDROME	Live-birth
Q900	TRISOMY 21	Live-birth
Q206	ISOMERISM (L) w BILAT SVCs & PAIRED AZYGOUS CONTIN TO SVCs	Live-birth
Q431	HIRSCHSPRUNG'S DISEASE	Live-birth

4.6.4. Other Gastrointestinal Abnormalities

Hirschsprung's Disease, (Q431)

Hirschsprung's disease is due to an absence of parasympathetic ganglion cells in the myenteric submucosal plexus of the rectum. This disorder sometimes extends to the colon. It occurs predominantly males with an incidence of 1:5000 births. Hirschsprung's disease typically presents with abdominal distension and failure of passage of meconium within the first 48hrs. Recognized associations include multiple endocrine neoplasia, Wardenburg's syndrome & Down syndrome.

Two cases were defined as primary disorders.

Q431	HIRSCHSPRUNG'S DISEASE	Male; Live-birth at term; Diagnosed 1- 4 weeks
Q431	HIRSCHSPRUNG'S DISEASE	Male; Live-birth at term; Diagnosed 1- 4 weeks

Foregut Duplication Cysts, (Q434)

Foregut duplication cysts are rare congenital anomalies of enteric origin. In majority of the patients, the diagnosis is made in infancy.

Q434 DUPLICATION CYST Live birth; Prenatal diagnosis

Duodenal Atresia, (Q410)

Duodenal atresia is seen in approximately 1:10,000 pregnancies. The classic 'double bubble' is due to dilatation of both stomach and the first part of the duodenum proximal to the obstruction. In 30% of cases it is associated with other disorder and in particular there is a well recognized association with Trisomy 21, (Down syndrome).

Two cases are described as isolated lesions in the primary position.

Q410	DUODENAL ATRESIA	Prenatal diagnosis; Live-birth;
Q410	DUODENAL ATRESIA	Prenatal diagnosis; Live-birth

Three further cases of duodenal atresia are recorded in association with chromosomal abnormality.

Q900	TRISOMY 21	Prenatal diagnosis; Live-birth
Q900	TRISOMY 21	Prenatal diagnosis; Live-birth
Q935	DELETION 1p22	Prenatal diagnosis; Live-birth

4.7. Renal & Urinary System

Renal tract abnormalities may be isolated or components of a recognizable syndromes. The ICD10 classification divides the abnormalities into renal agenesis and reduction defects, cystic kidney disease and congenital obstruction defects. Fetal renal tract anomalies will usually be detected at routine 20 week scan.

4.7.1. Renal Agenesis and Other Reduction Defects, (Q600, Q601, Q602)

These are typically the result of failure of the ureteric bud to develop so that the ureter and kidney are absent. If unilateral the child will live a full and healthy life provided the other kidney is normal. Bilateral agenesis is lethal and is usually diagnosed when profound oligohydramnios is seen on antenatal scan.

Bilateral Renal Agenesis, (Q601)

There were six cases recorded of bilateral renal agenesis. In each case prenatal diagnosis was achieved and the pregnancy terminated.

Q601	RENAL AGENESIS - BILAT	
Q601	RENAL AGENESIS - BILAT	
Q601	RENAL AGENESIS - BILAT	Agenesis of uterus, bladder and ureter.
Q601	RENAL AGENESIS - BILAT	Potter's Sequence
Q601	RENAL AGENESIS	
Q601	RENAL AGENESIS - BILAT	

Potter's Sequence is the result of oligohydramnios leading to pulmonary hypoplasia, low set ears, broad flattened nose and limb abnormalities. This deformation sequence can result from a number of pathological processes including pre-term rupture of membranes, polycystic or multicystic renal disease, and agenesis or obstruction of the ureter, but was initially intended to only refer to cases resulting from Bilateral Renal Agenesis, (the 'Classic' form).

Unilateral Renal Agenesis, (Q600)

A total of nine cases of unilateral renal agenesis were listed with a Male:Female ratio of 2:1. In all cases renal agenesis is given as the primary diagnosis. A prenatal diagnosis was made in eight cases. In the remaining case the diagnosis was made between 1 and 4 weeks.

Q600	ABSENT KIDNEY (L)	Live-birth; Male; Congenital uretheroceole; Imperforate anus
Q600	RENAL AGENESIS (L)	Live-birth; Male
Q600	ABSENT KIDNEY ®	Live-birth; Female
Q600	RENAL AGENESIS (L)	Live-birth; Male; Diagnosis 1-4 weeks
Q600	ABSENT KIDNEY ®	Live-birth; Male
Q600	ABSENT KIDNEY (L)	Live-birth; Female
Q600	ABSENT (L) KIDNEY	Live-birth; Female
Q600	ABSENT KIDNEY ®	Live-birth; Male
Q600	ABSENT KIDNEY (L)	Live-birth; Male

Unilateral renal agenesis is not usually of any major health consequence provided that the other kidney is healthy. However it is associated with an increased incidence of abnormality of the development of the female reproductive tract which may present as infertility.

4.7.2. Cystic Kidney Disease (Q611, Q614, Q6141)

Dysplastic kidneys contain abnormally differentiated parenchyma. They are commonly associated with obstruction and other abnormalities of the urinary tract. Eleven disorders are listed in the primary position. Prenatal diagnosis was achieved for all listed cases.

Q613	MULTICYSTIC KIDNEY (L)	Duplex kidney
Q613	POLYCYSTIC KIDNEY ®	
Q614	RENAL DYSPLASIA ®	Congenital hydronephrosis
Q6140	MULTICYSTIC DYSPLASTIC KIDNEY (L)	Congenital uretherocele
Q6140	MULTICYSTIC DYSPLASTIC KIDNEY ®	
Q6140	MULTICYSTIC DYSPLASTIC KIDNEY (L)	
Q6140	MULTICYSTIC DYSPLASTIC KIDNEY (L)	
Q6140	MULTICYSTIC DYSPLASTIC KIDNEY (L)	Cardiac abnormalities; Single umbilical artery
Q6140	MULTICYSTIC DYSPLASTIC KIDNEY (L)	Ectopic kidney
Q6140	MULTICYSTIC DYSPLASTIC KIDNEY ®	
Q6140	MULTICYSTIC DYSPLASTIC KIDNEY (L)	

The majority of cases were live births but there was one stillbirth at 33 weeks gestation associated with multiple cardiac abnormalities including malposition of the heart, coarctation of the aorta and VSD.

Dysplastic renal disease was a secondary diagnosis in five further cases.

Q606	POTTER'S SEQUENCE	Multicystic Dysplastic Kidney
Q630	DUPLEX KIDNEY ®	Multicystic Dysplastic Kidney; Live-birth
Q6431	CONGENITAL URETHRAL STRICTURE	Multicystic Dysplastic Kidney; Live-birth
Q758	POOR DEVELOPMENT OF MID-FACE	Renal dysplasia; Multiple abnormalities
Q318	LARYNGEAL STENOSIS	Renal dysplasia; Multiple abnormalities

In all five cases prenatal diagnosis was achieved. Three cases were terminated following prenatal diagnosis.

4.7.3. Congenital Obstructive Defects of Renal Pelvis & Malformation of Ureter, (Q62)

This ICD10 category includes a variety of abnormalities of the renal and urinary system including, congenital hydronephrosis, atresia and stenosis of the ureter, agenesis of ureter and congenital PUJ obstruction.

Congenital Hydronephrosis, (Q620)

Hydronephrosis is a common congenital condition that is usually first diagnosed on prenatal ultrasound. While there can be many conditions that lead to hydronephrosis, the most common causes are obstructions that reduce the ability of urine to flow out of the kidney and into the bladder. Many children who are diagnosed with hydronephrosis before they are born will have the condition resolve on its own without medical intervention.

Q620	CONGENITAL HYDRONEPHROSIS	Male; Prenatal diagnosis; Megaloureter
Q620	HYDRONEPHROSIS (L)	Male; Prenatal diagnosis; Ureteroceles
Q620	CONGENITAL HYDRONEPHROSIS (L)	Male; Prenatal diagnosis
Q620	CONGENITAL HYDRONEPHROSIS	Male; Prenatal diagnosis
Q620	CONGENITAL HYDRONEPHROSIS	Male; Prenatal diagnosis; Megaloureter
Q620	CONGENITAL HYDRONEPHROSIS (L)	Male; Prenatal diagnosis
Q620	CONGENITAL HYDRONEPHROSIS (L)	Male; Prenatal diagnosis

Congenital PUJ Obstruction, (Q6210)¹⁴

The most common cause of obstruction (blockage) in the urinary tract in children is a congenital obstruction at the point where the ureter joins the renal pelvis – the ureteropelvic junction, (UPJ or PUJ). Most PUJ obstructions are identified long before birth by prenatal scan. Urine is produced by the fetus at a rate that exceeds the amount able to drain out of the renal pelvis into the ureter. This causes accumulation of urine within the kidney and dilatation of the renal pelvis which is clearly visible on scan.

Although ‘renal pyelectasis’ a very common prenatal observation, congenital PUJ obstruction was only formally diagnosed in four cases.

Q6210	PUJ OBSTRUCTION ®	Male; Prenatal diagnosis
Q6210	PUJ OBSTRUCTION (L)	Male; Prenatal diagnosis
Q6210	PUJ OBSTRUCTION/HYDRONEPHROSIS ®	Male; Prenatal diagnosis
Q6210	PUJ OBSTRUCTION (L)	Female; Prenatal diagnosis

Where Congenital PUJ Obstruction appears as the primary abnormality prenatal diagnosis was always achieved.

Other obstructive Abnormalities of the Urinary System

Congenital obstructive defects are listed as secondary diagnoses in a further ten cases with a primary renal or urinary abnormality. The most common of these is the congenital ureterocele, (n=6). An ureterocele is a ballooning of the terminal ureter as it enters the bladder. It occurs when the inner part of the Wolffian duct is incompletely absorbed into the trigone. An ureterocele may also occur in an ectopic ureter or present as a ‘cyst’ near the external meatus in female infants. This most often occurs at the lowermost ureteric orifice in duplex systems, (see below).

4.7.4. Other Congenital Malformations of the Kidney, (Q63)

Duplex Kidney and Collecting System, (Q630)

Duplex kidneys are a relatively common abnormality. Duplex kidneys may be associated with ureterocele, ectopic ureter insertion or vesicoureteric reflux. The terminology surrounding duplex kidneys has, however, been conflicting. A true duplex kidney has two separate pelvi-calyceal systems. Most of the clinical problems relate to the way the ureters insert into the bladder: the ureter from the upper pole of a duplex kidney will have a more distal/ medial insertion into the bladder than the ureter from the lower pole. In general, the lower pole ureter of a complete duplex inserts more laterally into the bladder and will have a shorter and less oblique intramural course through the bladder wall than a normal ureter and this makes it more prone to reflux. Duplex kidney is listed as a primary diagnosis in ten cases, all live-births.

Q630	DUPLEX KIDNEY (L)	
Q630	DUPLEX KIDNEY ®	Congenital ureterocele
Q630	DUPLEX KIDNEY ®	
Q630	DUPLEX (L) KIDNEY	
Q630	DUPLEX KIDNEY ®	
Q630	DUPLEX KIDNEY ®	Multicystic dysplastic kidney
Q630	DUPLEX SYSTEM (L)	Anomaly of ureter
Q630	DUPLEX KIDNEY (L)	Congenital ureterocele
Q630	DUPLEX KIDNEY ®	Congenital ureterocele
Q630	DUPLEX KIDNEY (L)	Duplication of ureter; Preterm delivery

¹⁴ In previous reports the ICD10 code Q623 was used to define these abnormalities.

4.7.6. Hypospadias, (Q540, Q541, Q542, Q549)

Hypospadias describes an abnormality of male infants where the urethra opens on the ventral aspect of the penis at a point proximal to the normal site. The frenulum is almost always affected being imperfectly formed and this deformity may be more obvious than the hypospadias itself. Hypospadias is the commonest abnormality of the male genitalia and was the third commonest abnormality listed in the 2012-2013 data series. However there are only eight cases where hypospadias was recorded as the primary diagnosis in the current data. It is listed as a secondary diagnosis in a further four cases.

Q564	INDETERMINATE SEX	Live-birth at term
Q8704	GOLDENHAR SYNDROME	Live-birth at term
Q8710	AARSKOG-SCOTT SYNDROME	Live-birth at term
D821	DI GEORGE SYNDROME	Live-birth at term

4.8. Musculo-Skeletal Abnormalities

The congenital musculo-skeletal abnormalities vary greatly in extent and severity. They may be localized, (e.g. TEV, DDH), or generalized, (e.g. achondroplasia).

4.8.1. Developmental Dysplasia of the Hip, (Q6580, Q6581)

Dislocated hips are associated with joint laxity and acetabular dysplasia. Postural features often play a role in their causation. They are commonest in female infants, term deliveries, breech presentation and the left hip. Diagnosis is made at birth by specifically testing the hips.

A total of 10 cases of Congenital Dislocation of the Hip are listed. In nine cases DDH is the main diagnosis and in the remaining case is noted as a secondary abnormality in VACTERL association. In eight cases the abnormality is recorded as unilateral with the right hip more commonly affected than the left.

The majority of cases were diagnosed in the first week of life, (n=6, 60%). Two cases were not diagnosed until after one month.

All ten cases observed were in live-born female infants delivered at term.

4.8.2. Achondroplasia, (Q774)

Achondroplasia is a non-lethal short limb dysplasia which may not be apparent until the time of birth. A single cases of achondroplasia was diagnosed on scan at 37 weeks gestation.

Q774 ACHONDROPLASIA Live birth at term of male infant

4.8.3. Talipes Equino Varus, (Q660)

Minor degrees of talipes are common at birth, resulting from mechanical pressure *in utero*. The commonest deviation is one in which there is plantar flexion, (equinus), and foot adduction, (varus), at the mid-tarsal joint. The birth incidence is commonly stated as 1:1000. For the year 2013-2014 talipes equino varus, (TEV), is recorded in the primary diagnostic position on eleven occasions with a Male:Female ratio of 4.5:1. The majority of cases, (n=9, 81.8%) were diagnosed on antenatal scan.

Talipes equino varus is also coded as a secondary diagnosis in a further six cases. A prenatal diagnosis is recorded in five of these cases but this may relate to the primary diagnosis rather than the finding of talipes. However, prenatal detection of talipes is known to improve when bilateral or associated with other malformation.

Q743	ARTHROGRYPOSIS MULTIPLEX CONGENITA	Live-birth
Q748	HYPEREXTENDED LEGS	Termination
Q792	EXOMPHALOS	Fetal loss at 15 weeks
Q8706	MOEBIUS SYNDROME	Live-birth
E840	CYSTIC FIBROSIS	Live-birth; Diagnosis at 1 – 4 weeks
Q234	HYPOPLASTIC (L) HEART	Termination

A related case of talipes calaneovarus, (Q661), was also seen in female infant delivered at term.

4.8.4. Limb Reduction Defects, (Q71, Q72).

Limb reduction defects are defined by the absence or severe hypoplasia of limb skeletal structures. They are rare and in their milder presentations frequently missed antenatally. Three cases are listed as primary limb reduction abnormalities. All were live-births at term.

Q710	ABSENT UPPER LIMBS	Prenatal diagnosis
Q713	ABSENT (L) HAND - FINGER BUDS ONLY	Prenatal diagnosis
Q7131	HYPOPLASTIC (L) THUMB	Diagnosis at birth

One or more limb reduction defects are listed as secondary abnormalities in a further four cases.

Q935	DELETION 1p22	Multiple abnormalities
D610	FANCONI'S ANAEMIA	Prenatal diagnosis; Termination
Q220	PULMONARY ATRESIA	
Q758	POOR DEVELOPMENT OF MID-FACE	

Fetal forearm defects are often associated with underlying genetic syndromes or aneuploidy, particularly when bilateral. Limb reduction defects are also associated with certain common medications including clomiphene and SSRI's .

A female infant with a deletion of 1p22 was delivered at 37 weeks gestation following the demonstration of multiple fetal abnormalities at sixteen weeks gestation. The most striking feature was of bilateral symmetrical reduction and flexion deformities of both radius and hands. The differential diagnosis was of TAR syndrome, Holt-Oram syndrome, Duane-radial Ray anomaly and Fanconi's anaemia. Amniocentesis was performed and karyotype confirmed¹⁵. Chromosome breakage studies for Fanconi's anaemia were normal. Other features included duodenal atresia and plagiocephaly. Excellent 3D ultrasound images proved to be invaluable in counselling and management of this case.

4.8.5. Craniosynostosis (Q750)

Craniosynostosis is due to the premature closure of one or more of the skull sutures. It affects about 1:2500 children. Craniosynostosis causes distortion of the shape of the skull owing both to failure of bone growth at the prematurely closed suture site and to compensatory overgrowth at the sutures that remain open. The different types of craniosynostosis are classified by which sutures have closed prematurely. One primary case is described.

Q750	CRANIOSYNOSTOSIS	Male; Diagnosis at birth
------	------------------	--------------------------

4.8.6. Other Musculo-Skeletal Abnormalities

Arthrogyposis, (Q743)

Arthrogyposis is not really a diagnosis but a description that refers to a number of pathological processes resulting in limb immobilization and multiple congenital joint contractures. It is therefore a rather heterogenous grouping of conditions both syndromic, (e.g. Larsen syndrome, Freeman-Shelden syndrome and Multiple Pterigium syndrome) and non-syndromic. Two cases were described, both in the primary diagnostic position.

Q743	ARTHROGRYPOSIS	Prenatal diagnosis; Termination
Q743	ARTHROGRYPOSIS MULTIPLEX CONGENITA	Prenatal diagnosis; Live-birth

¹⁵ Other data associated with this case confirms that the karyotype was actually reported as 46, XX, t(1:12)(p13; q22).

Features associated with arthrogryposis included talipes, cystic hygroma and micrognathia.

Congenital Malformations of the spine not associated with scoliosis, (Q764)

This is a broad classification under ICD10 and includes fusion of the spine, absence of vertebrae, hemi-vertebrae, malformation of the lumbo-sacral joint and supernumerary vertebrae. Congenital malformation of the spine was an associated feature in three cases.

Q8726 VACTERL ASSOCIATION

Q341 FOREGUT DUPLICATION CYST POSTERIOR MEDIASTINUM

Q4200 IMPERFORATE ANUS/RECTO-PROSTATIC URETHRAL FISTULA

4.9. Abdominal Wall Defect

ICD10 Codes Q790-Q799 are 'Congenital malformations of the musculoskeletal system, NEC' and includes Congenital Diaphragmatic Hernia, Exomphalos, Gastroschisis and Amniotic Rupture Sequence - collectively considered here as 'Abdominal Wall Defects'.

4.9.1. Congenital Diaphragmatic Hernia, (Q790, Q791)

Diaphragmatic hernia, a unilateral or bilateral diaphragmatic defect allowing abdominal viscera to herniate into the chest, is relatively common and occurs in 1:2500 live births. It is a consequence of deficient closure of the pleuroperitoneal duct. Pre-natal diagnosis is typically based on the ultrasound finding of fluid-filled stomach or bowel within the thoracic cavity. Prognosis depends on the size of the defect, the presence of accompanying anomalies and preparation for intervention following early diagnosis.

A total of four cases were described in 2013-2014. In two cases a 'straightforward' diaphragmatic hernia was the primary diagnosis.

Q790	DIAPHRAGMATIC HERNIA (L)	Prenatal diagnosis; Live-birth
Q790	DIAPHRAGMATIC HERNIA	Live-birth; Diagnosed between 1 and 12 months

Congenital diaphragmatic hernia was also classified as a secondary diagnosis as part of Fryn's syndrome.

Q878	FRYNS SYNDROME	Prenatal diagnosis; Termination
------	----------------	---------------------------------

Fryn's syndrome is typically characterised by a diaphragmatic defect, abnormalities of the fingers and toes and distinct facial features such as hypotelorism, large mouth, small chin, microphthalmia, and cleft lip/palate. It is said to be the most common autosomal recessive condition associated with diaphragmatic hernia and accounts for 1-10% of all cases of CDH. The case described above was associated with hypotelorism, micrognathia, and malrotation of the gut.

A further case involving a congenital anterior diaphragmatic hernia was recorded.

Q897	PENTALOGY OF CANTRELL	Prenatal diagnosis; Termination at 13 weeks
------	-----------------------	---

Pentalogy of Cantrell, (or more accurately Cantrell-Haller-Ravich syndrome), is exceptionally rare¹⁶. The syndrome describes a spectrum of midline thoraco-abdominal defects typically involving the supra-umbilical wall, lower sternum, anterior diaphragm and diaphragmatic pericardium. These can result in exomphalos, parietal herniation of the heart and other cardiothoracic abnormalities such as sternal clefts and VSD. The case described above included ectopia cordis with the fetal heart located partially outside of the thorax¹⁷.

4.9.2. Gastroschisis, (Q793)

Gastroschisis is an open, sporadically occurring, abdominal wall defect with extruded loops of bowel. It develops between the 5th and 6th week of embryonic development. Instead of the physiological herniation of bowel into the umbilical cord a rupture forms in the ventral abdominal wall lateral to

¹⁶ Cantrell JR, Haller JA, Ravich MM. Surg. Gynecol. Obstet. 1957; 107(5): 602-614

¹⁷ This is a presumption made from the use of the ICD10 code Q248 as a secondary diagnosis. Ectopia cordis certainly maps to this code but Q248 can also be used for any 'Other Specified Malformation of the Heart' including (for example) diverticulum of the left ventricle or even Uhl disease.

the umbilical cord insertion allowing the free extrusion of bowel loops. It is likely that the rupture is a consequence of the premature obliteration of the right umbilical vein creating a weakness in the abdominal wall.

Four cases of gastroschisis were diagnosed on antenatal scan. There were no associated abnormalities; gastroschisis was an isolated lesion in all cases. They were all live-births with a mean gestation at delivery of 35 weeks. Looking at the data from previous reports pre-term delivery seems to be a feature of these cases. It is difficult to know from the data if this is iatrogenic. Gastroschisis is certainly associated with a young maternal age and it is said that mother's under the age of 20 years are twelve times more likely to have an infant with gastroschisis than the general obstetric population. In this small series the mean maternal age was 26 years, (range 20 – 32 years).

4.9.3. Exomphalos, (Q792)

Exomphalos is the result of the physiological herniation of the gut into the umbilical cord and the failure of the intestinal loops to return to the fetal abdomen. Typically membrane covered, it is often seen with associated malformations.

Only two cases of exomphalos are coded in the data for 2013-2014. It is given as the primary diagnosis in one case which was associated with a mosaic whole chromosome monosomy and talipes equinovarus.

Q792 EXOMPHALOS Prenatal diagnosis at 12 weeks; Fetal loss at 15 weeks

Exomphalos was an associated feature in a case of Trisomy 18.

Q910 TRISOMY 18 Prenatal diagnosis; Termination at 13 weeks

4.9.4. Amniotic Band Sequence, (Q7980)

The commonly accepted view is that amniotic band sequence is a consequence of amniotic rupture without injury to the chorion. Fibrous bands of the ruptured amnion 'float' and can encircle and trap fetal parts. Later as the fetus grows but the bands do not, the bands become constricting. In some cases a complete amputation of a digit or limb may occur. Amniotic bands can also attach to the face or neck causing deformities such as cleft lip and palate.

A single case of Amniotic Band Sequence is listed and was associated with abnormalities of the skull and face.

Q7980 AMNIOTIC BAND Prenatal diagnosis; Termination at 11 weeks

4.10. Chromosomal Abnormality

A chromosomal abnormality is recorded in the primary or secondary position for 82 cases, (25.2%). They account for 14.7% of all abnormalities detected in the 2013-2014 cohort. The majority, (n=77, 94%), are recorded as the primary diagnosis, (Figure 4.10). The majority of cases were diagnosed prenatally, (Figure 4.11). Termination was the predominant pregnancy outcome, (Figure 4.12).

Figure 4.10: Overview of Primary Chromosomal Abnormality, (Simplified)

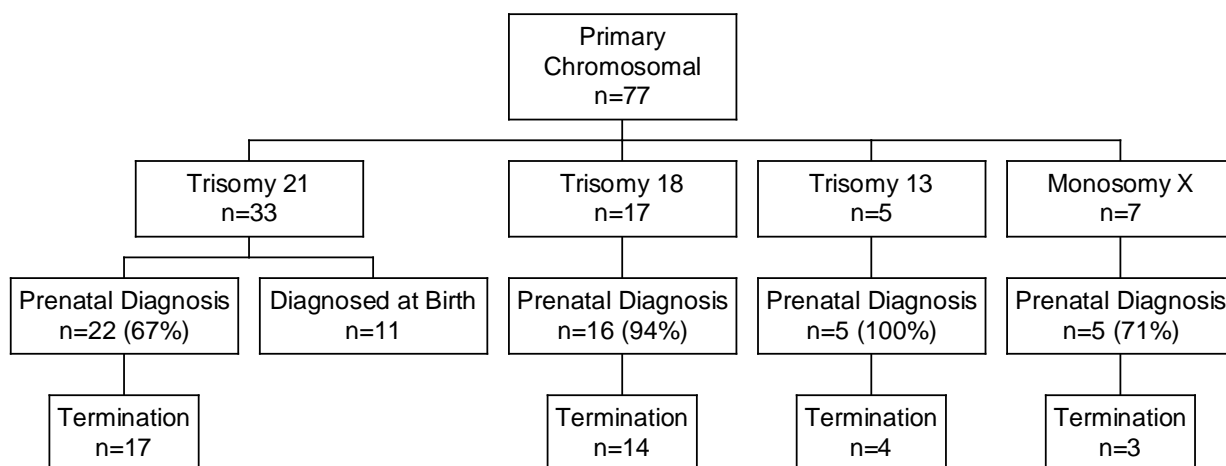


Figure 4.11: Point of Diagnosis of Primary Chromosomal Abnormality, (n=77)

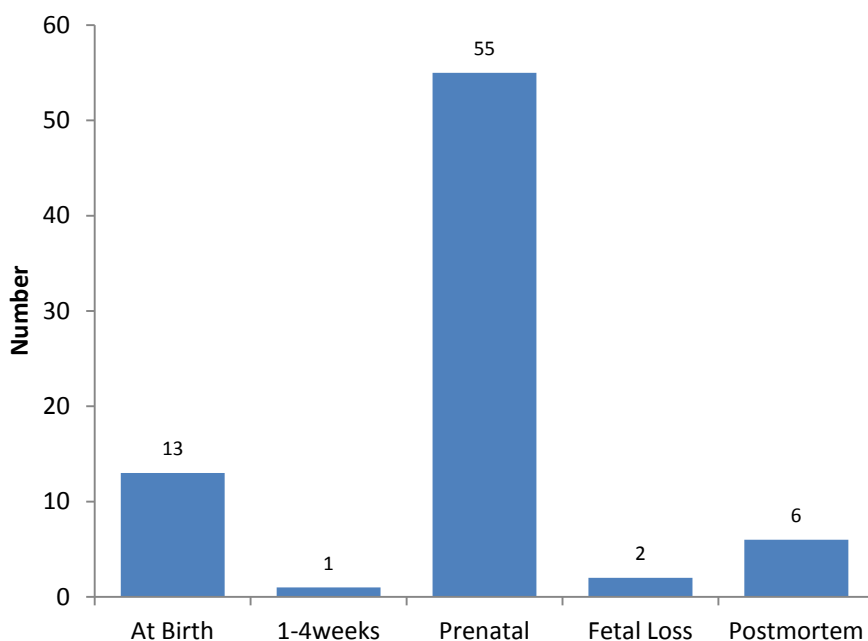
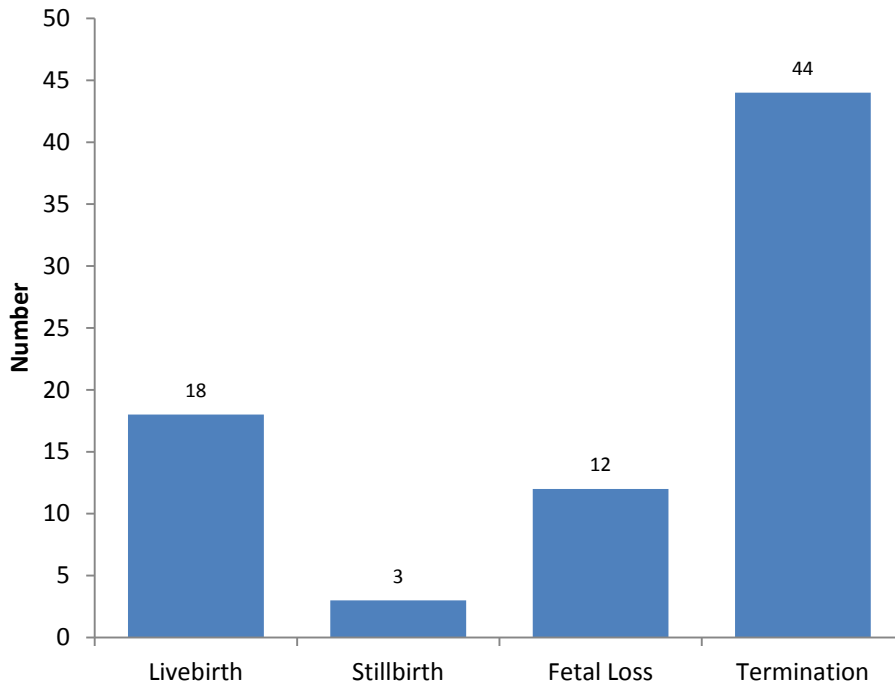


Figure 4.12: Outcome of Pregnancy with Primary Chromosomal Abnormality, (n=77)



4.10.1. Trisomy 21 (Down Syndrome), (Q900, Q909)

A total of 33 cases were associated with Trisomy 21, (incidence of 1:403 maternities). Trisomy 21 was always recorded as a primary abnormality. Forty-two percent of cases, (n=14), were live born. There were two stillbirths following prenatal diagnosis, both at 32 weeks gestation. The remaining seventeen cases were terminated following prenatal diagnosis, (Figure 4.13).

Figure 4.13: Outcome of pregnancies associated with Trisomy 21, (n=33)

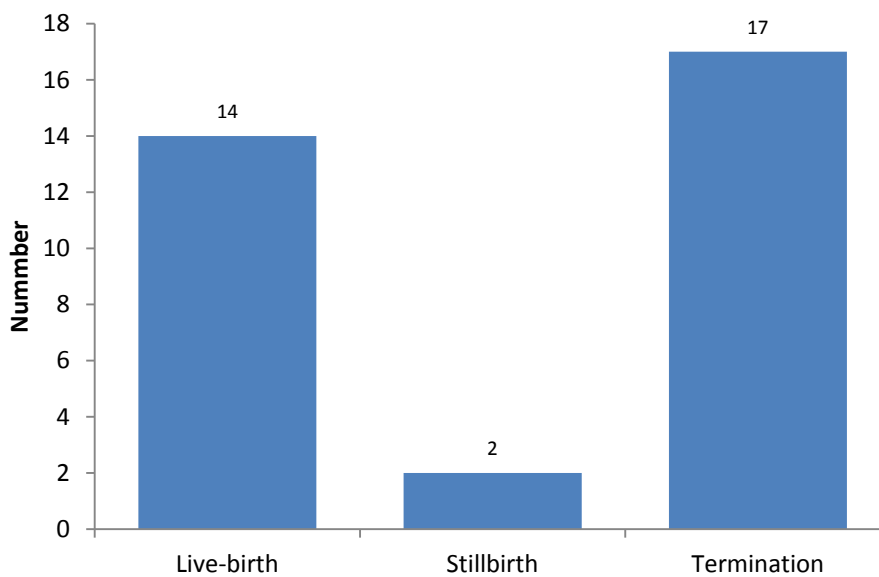
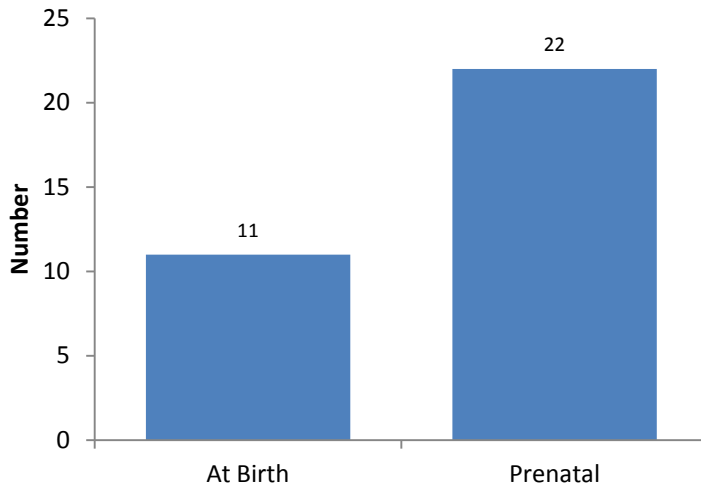


Figure 4.14: Point of diagnosis of Trisomy 21, (n=33)



With regards to the diagnoses made at birth,(Figure 4.14), some data is available from the Pregnancy & Newborn Screening system on whether or not women were offered antenatal screening for Down syndrome. It emerges that eight women did elect to have screening for Down syndrome - six cases were low risk on screening but two cases were high risk and declined invasive testing. There were two further cases where an offer of screening was made but declined and one late booker.

4.10.2. Trisomy 18, (Q910)

There were 17 cases of Trisomy 18 (Edward’s syndrome) listed in the data. The majority, (n=16, 94%), were diagnosed antenatally. Trisomy 18 was diagnosed in a fetal loss at 11 weeks, (prior to any prenatal diagnosis).

Q910	TRISOMY 18	Prenatal diagnosis; Termination
Q910	TRISOMY 18	Cystic hygroma; Cardiac abnormality; Prenatal diagnosis; Termination
Q910	TRISOMY 18	Prenatal diagnosis; Termination
Q910	TRISOMY 18	Prenatal diagnosis; AVSD; Stillbirth at 35 weeks
Q910	TRISOMY 18	Prenatal diagnosis; Termination
Q910	TRISOMY 18	Prenatal diagnosis; Termination
Q910	TRISOMY 18	Cystic hygroma; Holoprosencephaly; Prenatal diagnosis; Termination
Q910	TRISOMY 18	Prenatal diagnosis; Exomphalos; Termination
Q910	TRISOMY 18	Prenatal diagnosis; VSD; Termination
Q910	TRISOMY 18	Prenatal diagnosis; Termination
Q910	TRISOMY 18	Prenatal diagnosis; Termination
Q910	TRISOMY 18	Anencephaly; Prenatal diagnosis; Termination
Q910	TRISOMY 18	Prenatal diagnosis; Termination
Q910	TRISOMY 18	Cystic hygroma; Prenatal diagnosis at 11 weeks; Fetal loss at 16 weeks
Q910	TRISOMY 18	Prenatal diagnosis; Termination
Q910	TRISOMY 18	Fetal loss at 11 weeks
Q910	TRISOMY 18	Prenatal diagnosis; Termination

Cardiac abnormalities are commonly associated with Trisomy 18 yet are seen in only three cases, (17.6%) in this series.

4.10.3. Trisomy 13, (Q914, Q917)

There were 5 listed cases of Trisomy 13, (Patau's syndrome). All were diagnosed antenatally. Holoprosencephaly was an associated feature in one case.

Q914	TRISOMY 13	Cleft lip and palate; Prenatal diagnosis; Termination
Q914	TRISOMY 13	Cystic hygroma; Prenatal diagnosis; Fetal loss
Q914	TRISOMY 13	Prenatal diagnosis; Termination
Q914	TRISOMY 13	Prenatal diagnosis; Termination
Q914	TRISOMY 13	Holoprosencephaly; Prenatal diagnosis; Termination

4.10.4. Polyploidy: Triploidy & Tetraploidy, (Q927)

Polyploidy refers to a numerical change in a whole set of chromosomes, (whereas aneuploidy refers to a numerical change in part of a chromosome set). Triploidy, (69 XXY, XXX or XYY), in which the fetus gains a complete extra set of chromosomes, is thought to occur in up to 2% of conceptions and 15% of miscarriages.

Q927	TRIPLOIDY	Prenatal diagnosis; Termination of pregnancy
------	-----------	--

Triploidy may also result as a consequence of either digyny (the extra haploid set is from the mother) or diandry (the extra haploid set is from the father). Diandry is mostly caused by reduplication of the paternal haploid set from a single sperm or as a result of dispermic fertilization. Digyny is most commonly caused by either failure of one meiotic division during oogenesis leading to a diploid oocyte or failure to extrude one polar body from the oocyte.

Complete tetraploidy, (92XXXX), is more rarely diagnosed than triploidy, but is observed in 1–2% of early miscarriages.

Q927	TETRAPLOIDY	Fetal loss at 11 weeks; Diagnosis on post-mortem
------	-------------	--

4.10.5. Turner Syndrome, (Q960, Q969)

Turner syndrome is an aneuploidy, and is also known as 'monosomy X', (45XO). The incidence is roughly 1:2500 live-born girls. Fifteen percent of cases demonstrate some mosaicism. Sometimes a lymphangioma, (cystic hygroma), prompts diagnostic investigation. Seven cases were diagnosed prenatally.

Q960	TURNERS SYNDROME	Fetal loss
Q960	TURNER SYNDROME	Prenatal diagnosis; Termination
Q960	TURNER (MONOSOMY X) SYNDROME	Fetal loss
Q960	TURNER SYNDROME	Prenatal diagnosis; Termination
Q960	TURNER SYNDROME	Prenatal diagnosis; Termination
Q960	TURNER SYNDROME	Cystic hygroma; Prenatal diagnosis; Fetal loss
Q969	TURNER SYNDROME	Fetal loss

4.10.6. Klinefelter Syndrome, (Q980)

Klinefelter syndrome, (47, XXY), affects 1:1000 males and is typically diagnosed in early adulthood during investigations of infertility. There are two cases where the diagnosis of Klinefelter syndrome is in the primary position.

Q980	KLINFELTER SYNDROME	Live-born at 38 weeks gestation; Diagnosis at birth
Q980	KLINFELTER SYNDROME	Prenatal diagnosis; Termination of pregnancy

However two further cases of Klinefelter syndrome are classified in association with other aneuploidy.

Q998	TRISOMY 15	Fetal Loss; Diagnosis at post-mortem examination
Q900	TRISOMY 21	Live-birth at term; Indeterminate sex

4.10.7. Other Specified Chromosome Abnormalities, (Q998)

This is an ICD10 'place-holder' for chromosomal abnormalities that are 'not elsewhere categorized'. A total of seven cases are seen, all in the primary position.

Q998	PERICENTRIC INVERSION CHROM 11 & TERMINAL DEL CHROM 7	Termination
Q998	TRISOMY 16	Fetal loss
Q998	UNBAL TRANSLOC: 10q24 DUPLICATION & 4q13 DELETION	Live-birth
Q998	UNBALANCED TRANSLOCATION	Termination
Q998	TRISOMY 15	Fetal loss
Q998	TRISOMY 15	Fetal loss
Q998	TRISOMY 15	Fetal loss

Pericentric inversion of chromosome 11 with terminal deletion of chromosome 7 was detected on amniocentesis at 15 weeks gestation. The indication for amniocentesis is not recorded. Termination of pregnancy was undertaken at 18 weeks gestation. No associated abnormalities are listed.

The diagnosis of an unbalanced translocation: 10q24 duplication & 4p13 deletion was made following the live-birth of a male infant with both congenital pulmonary valve stenosis and cleft lip & palate. There had been no suggestion of abnormality on prenatal scan.

Termination of pregnancy was performed for an unbalanced translocation at 12 weeks gestation. The diagnosis had been made at 11 weeks, presumably following chorionic villus sampling. No associated abnormalities are listed. The indication for invasive testing is not given.

The case of Trisomy 16 was a spontaneous pregnancy loss at 11 weeks gestation. Diagnosis was made at post-mortem. Trisomy 16 is said to be the second most common cause of spontaneous pregnancy loss after monosomy X, (Turner syndrome).

Chromosome 15 spans more than 102M base pairs and alone accounts for more than 3% of the total DNA in the human genome. Complete Trisomy 15 is therefore lethal and indeed the three cases listed above were associated with 1st trimester spontaneous pregnancy loss. One case was a male fetus with an additional X chromosome – essentially Trisomy 15 with Klinefelter – and has already been mentioned above.

Appendix 1

NHS Greater Glasgow & Clyde Maternities 1st April 2013 - 31st March 2014

Source: Pregnancy & Newborn Screening System, June 2014

	Appointed Referrals Non-NHSGGC Residents	Appointed Referrals NHSGGC Residents	Total Appointed Referrals	Bookers Non-NHSGGC Residents	Bookers NHSGGC Residents	Total Bookers
Princess Royal Maternity	1154	5920	7074	1016	5188	6204
Royal Alexandra Hospital	376	3415	3791	338	3166	3504
Southern General Hospital	379	6851	7230	333	6011	6344
Not recorded	78	182	260	78	182	260
Total	1987	16368	18355	1765	14547	16312

Appendix 2

Case Prevalence Comparison, (per 10,000 births) ‡.

Abnormality	Prevalence in Primary Position	Prevalence in any Position	EUROCAT Prevalence Data*
Amniotic Band Sequence, (Q7980)	0.75	0.75	0.51
CCAM,(Q338)	1.50	2.25	0.95
Bilateral Renal Agenesis, (Q602)	4.50	4.50	1.18
Congenital cataract, (Q120)	1.50	2.25	1.23
Hirschsprung's Disease, (Q431)	1.50	1.50	1.24
Turner Syndrome, (Q914-917)(Q960-969)	2.25	2.25	2.24
Craniosynostosis, (Q750)	0.75	0.75	2.39
Hypoplastic Left Heart, (Q234)	2.25	2.25	2.66
Congenital Diaphragmatic Hernia, (Q790)	1.50	2.25	2.76
Gastroschisis, (Q793)	3.00	3.00	2.85
Exomphalos, (Q792)	0.00	0.75	3.00
Fallot's Tetralogy, (Q213)	6.00	6.75	3.45
Transposition of Great Arteries, (Q203)	0.75	3.00	3.52
Coarctation of the aorta, (Q251)	2.25	3.75	3.85
Atrioventricular septal defect, (Q212)	N/A	5.25	4.09
Edwards Syndrome, (Q910-913)	11.26	12.76	5.13
Hydrocephalus, (Q030-039)	N/A	N/A	5.77
Hip dislocation and/or dysplasia, (Q651)	6.75	7.51	8.07
Cleft Lip/Palate, (Q352-3799)	12.01	16.52	8.77
NTD's, (Q000,Q010-019, Q051-059)	14.26	16.52	9.66
Hypospadias, (Q549)	6.00	9.00	18.01
Down Syndrome, (Q900-909)	24.77	24.77	22.1

‡Denominators: The congenital anomaly surveillance tool that has been used to compile the data within this report is restricted to mothers' resident within the geographically defined area of NHS GG&C at the time of birth. In order to allow comparison with the EUROCAT prevalence data the appropriate denominator for the prevalence data is therefore the total live births and stillbirths for that area between 1st April 2013 and 31st March 2014 which is 13,321, (13,265 live births and 56 stillbirths). Data was extracted on 9th July 2014. EUROCAT prevalence data excludes fetal losses/deaths less than 20 weeks gestation i.e. four cases of Turner syndrome are excluded from the data.

*Source for comparison data: EUROCAT Website Database. The EUROCAT prevalence data quoted is for 2007-2011.

Appendix 3

Prenatal Detection Rates: Comparison with 'established' data

Abnormality	Observed Prenatal Detection Rate	Expected Detection Rate*
Anencephaly	100%	98% (96.7%)
Spina Bifida	90%	90% (82.9%)
Diaphragmatic Hernia (Q790)	67%	60% (58.0%)
Cleft Lip ◊	93.8%	75% (50.7%)
Gastroschisis	100%	98% (91.6%)
Exomphalos	100%	80% (83%)
Serious Cardiac Abnormalities (EUROCAT defined)	60.0%	50%
Transposition of Great Vessels (Q203)	100%	(41.4%)
Atrioventricular septal defect (Q212)	57.1%	
Fallot's Tetralogy (Q213)	67%	
Ebstein's Anomaly (Q225)	N/A	
Hypoplastic Left Heart (Q234)	100%	(71.9%)
Hypoplastic Right Heart (Q226)	100%	
Coarctation of Aorta (Q251)	80%	
Bilateral Renal Agenesis	100%	84% (88.1%)
Talipes Equino-varus	82%	(39.8%)
Trisomy 21	67%	95% (63.8%)
Trisomy 18	94%	95% (90.9%)
Trisomy 13	100%	95% (90.9%)

◊ Figures vary depending on whether or not looking at cleft lip alone, in combination with palate defect, or as part of a complex or syndrome. Figure given is for **any** cleft lip, (primary or secondary abnormality, isolated or in association with cleft palate).

*Ward P & Soothill P. Fetal Anomaly ultrasound scanning: the development of a national programme for England. TOG 2011; 13: 211-217. Figures in brackets relate to EUROCAT observed Prenatal Detection Rates.